

ID NUMBER:

<input type="text"/>	<input type="text"/>	<input type="text"/>	<input type="text"/>	<input type="text"/>
----------------------	----------------------	----------------------	----------------------	----------------------

University Hospital, Geelong
Emergency Medicine
Trial Fellowship Exam
Short Answer Questions (SAQ)
Week 19

DIRECTIONS TO CANDIDATE

1. Answer each question in the space provided in this question paper.
2. Do not write your name on this question paper.
3. Enter your examination number in the space below.
4. Cross out any errors completely.
5. Do not begin the exam until instructed to do so.
6. Do not take examination paper or materials from this room.
7. The booklet binder may be removed during the exam.

QUESTION & ANSWER
BOOKLET

Question 1 (18 marks)

A 10 year old girl presents to the emergency department after a fall from the monkey bars after school and complains of a painful elbow.

An elbow X-ray is taken- refer to the prop booklet page 2.

a. State four (4) abnormalities shown in this xray. (4 marks)

- 1. _____
- 2. _____
- 3. _____
- 4. _____

After full assessment, the girl is confirmed to have this isolated injury and is very distressed with pain. She is fasted. She has received no prehospital treatment. She does not currently have IV access.

b. List your approach to analgesia in the first 20 minutes of this presentation. State five (5) points, providing dose and route where applicable. (5 marks)

- 1. _____
- 2. _____
- 3. _____
- 4. _____
- 5. _____

Question 1 continued

c. List four (4) indications for corrective treatment of this injury in the emergency department. (4 marks)

1. _____
2. _____
3. _____
4. _____

Question 1 continued

An indication for urgent corrective treatment exists.

In preparation for this corrective treatment, you attempt cannulation and fail 3 attempts. The patient's mother becomes very distressed and requests no further attempts at cannulation. She is verbally aggressive towards you. Corrective treatment is still required semi urgently.

d. State five (5) points to demonstrate how you would handle this situation. (5 marks)

1. _____

2. _____

3. _____

4. _____

5. _____

Question 2 (14 marks)

A 24 year old woman who is pregnant presents with per vaginal bleeding.

- a. Complete the table, listing the expected findings at each stated stage of a normal pregnancy. (12 marks)

Stage of pregnancy	Approximate Quantative BHCG (3 marks)	Transvaginal ultrasound (3 marks)	Transabdominal ultrasound (3 marks)
5 weeks			
6 weeks			
7 weeks			

Question 2 continued

b. State three (3) specific findings on ultrasound that define a failure of pregnancy. (3 marks)

1. _____

2. _____

3. _____

Question 3 (12 marks)

A 65 year old male presents with 4 days of scrotal pain.

A photo of the patient is taken- refer to the prop booklet page 3.

a. What is the diagnosis? (1 marks)

b. What is the significance of this condition? State three (3) points of significance. (3 marks)

1.

2.

3.

c. List two (2) risk factors for the development of this condition? State two (2) points of significance. (2 marks)

1.

2.

Question 3 (Continued)

Analgesia is provided. Disposition is arranged.

- d. List two (2) key treatment steps that you would institute in the first 20 minutes of your care. Provide one (1) justification for each choice. (4 marks)

	Treatment step (2 marks)	Justification (2 marks)
1		
2		

- e. List two (2) treatment methods that are utilised for definitive treatment. (2 marks)

1. _____

2. _____

Question 4 (12 marks)

A 25 year old man is intubated for decreased conscious state following a polydrug overdose. The patient remains in your emergency department overnight. Following your ward round in the morning you assess the patient as being suitable for extubation.

- a. List four (4) patient factors that are required to allow safe extubation of this patient. For each factor, state how you would ensure adequacy. (8 marks)

	Patient factor (4 marks)	How would you ensure adequacy of the factor (4 marks)
1.		
2.		
3.		
4.		

Question 4 (continued)

You successfully perform extubation.

b. List four (4) steps in your post- extubation care for this patient. (4 marks)

1. _____

2. _____

3. _____

4. _____

Question 5 (11 marks)

A 75 year old man presents following a collapse.

An ECG is taken- refer to the prop booklet page 4.

a. State five (5) abnormalities shown in this ECG. (5 marks)

1. _____
2. _____
3. _____
4. _____
5. _____

Question 5 (continued)

b. List six (6) possible causes for this ECG problem. (6 marks)

1. _____
2. _____
3. _____
4. _____
5. _____
6. _____

Question 6 (12 marks)

A 35 year old man presents with right sided facial swelling 24 hours after bilateral wisdom tooth removal.

A CT is taken- refer to the prop booklet page 5 and 6.

a. State two (2) abnormal findings in the CT scan slice labelled 1. (2 marks)

1. _____

2. _____

b. State two (2) abnormal findings in the CT scan slice labelled 2. (2 marks)

1. _____

2. _____

c. State two (2) abnormal findings in the CT scan labelled 3. (2 marks)

1. _____

2. _____

Question 6 (continued)

d. List six (6) likely complications of this condition. (6 marks)

1. _____

2. _____

3. _____

4. _____

5. _____

6. _____

Question 7 (11 marks)

A 74 year old man is brought to your emergency department with 1 week of shortness of breath and chest pain.

His observations are:

BP	135/870	mmHg supine
HR	110	/min
Temperature	38 °C	

Arterial blood gases and serum biochemical results are taken- refer to the props booklet page 7.

- a. Provide two (2) calculations to help you to interpret these results. State the significance of each finding. (4 marks)

Derived value 1: _____

Significance: _____

Derived value 2: _____

Significance: _____

- b. Using the scenario and the derived values, state the primary acid/base abnormality/s. State two (2) points. (2 marks)

1. _____

2. _____

Question 7 (continued)

c. List five (5) likely unifying causes for these pathological findings for this patient. (5 marks)

1. _____

2. _____

3. _____

4. _____

5. _____

Question 8 (12 marks)

A 65 year old man presents with a headache. He has not experienced trauma prior to the headache onset.

His observations are:

BP	255/150	mmHg supine
HR	90	/min
Temperature	37°C	

- a. Other than phaeochromocytoma and idiopathic hypertension, list six (6) likely underlying causes for his hypertension. (6 marks)

1. _____
2. _____
3. _____
4. _____
5. _____
6. _____

You have a strong suspicion of the diagnosis of phaeochromocytoma.

- b. List three (3) drugs in your preferred regime to treat the blood pressure in this setting (doses are not required). (3 marks)

1. _____
2. _____
3. _____

Question 8 continued

- c. List three (3) investigations that may be performed to assist in confirmation of the diagnosis of pheochromocytoma. (3 marks)

1. _____
2. _____
3. _____

Question 9 (16 marks)

A 35 year old man presents to your emergency department after a high voltage electrical injury.

A photograph of the man is taken- refer to the props booklet page 8

a. State four (4) features of this photograph that suggest a significant injury. (4 marks)

1. _____

2. _____

3. _____

4. _____

Question 9 (continued)

b. List six (6) systemic/ distant complications from the passage of high current through the body. (6 marks)

1. _____

2. _____

3. _____

4. _____

5. _____

6. _____

c. What is the role of the presenting ECG in household (240V) electrical exposure? State two (2) points in your answer. (2 marks)

1. _____

2. _____

Question 9 (continued)

d. List six (6) indications for ongoing ECG monitoring following an electrical exposure. (6 marks)

1. _____
2. _____
3. _____
4. _____
5. _____
6. _____

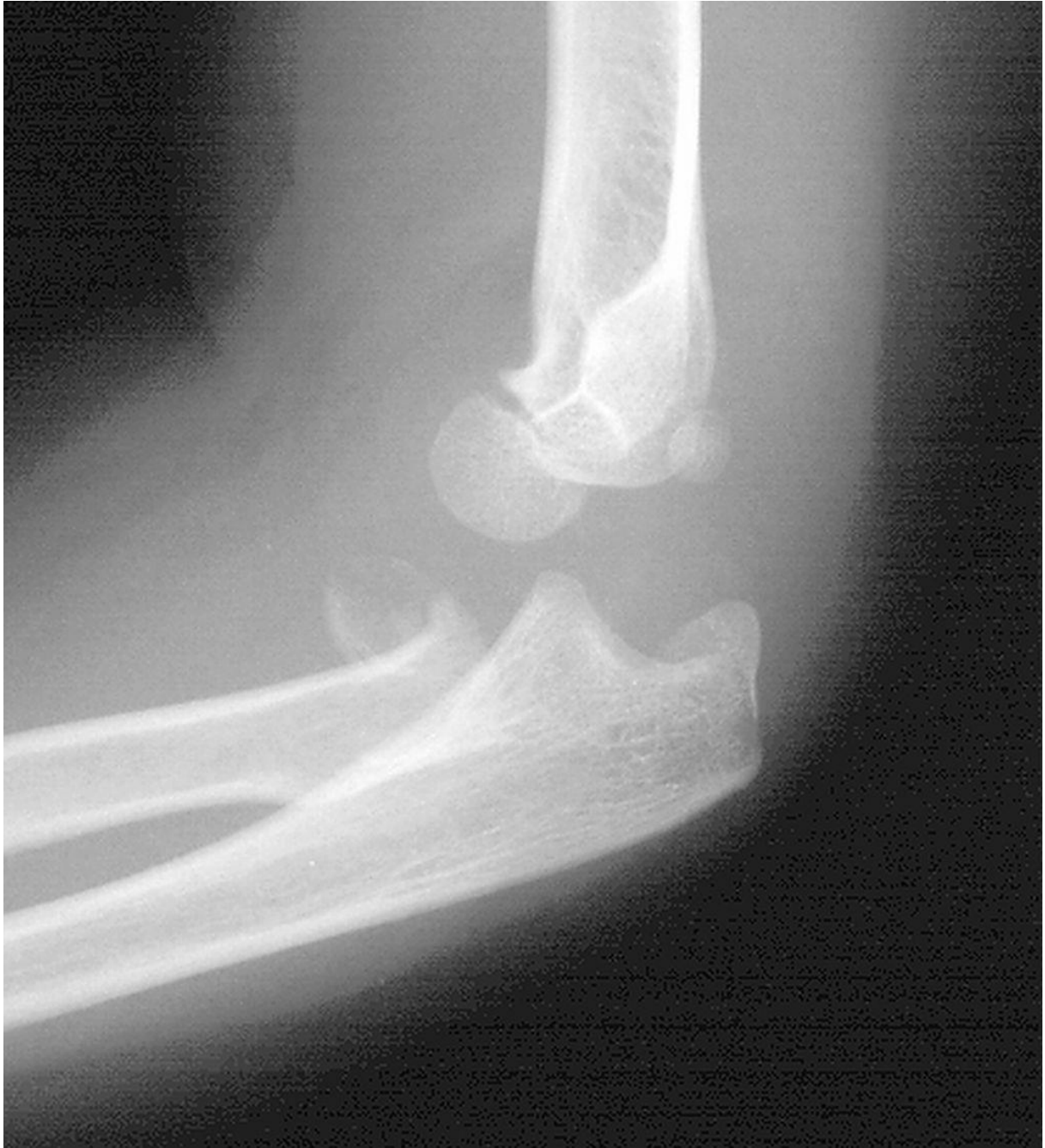
University Hospital, Geelong- Fellowship Exam Short Answer Questions
Week 19

ID NUMBER:

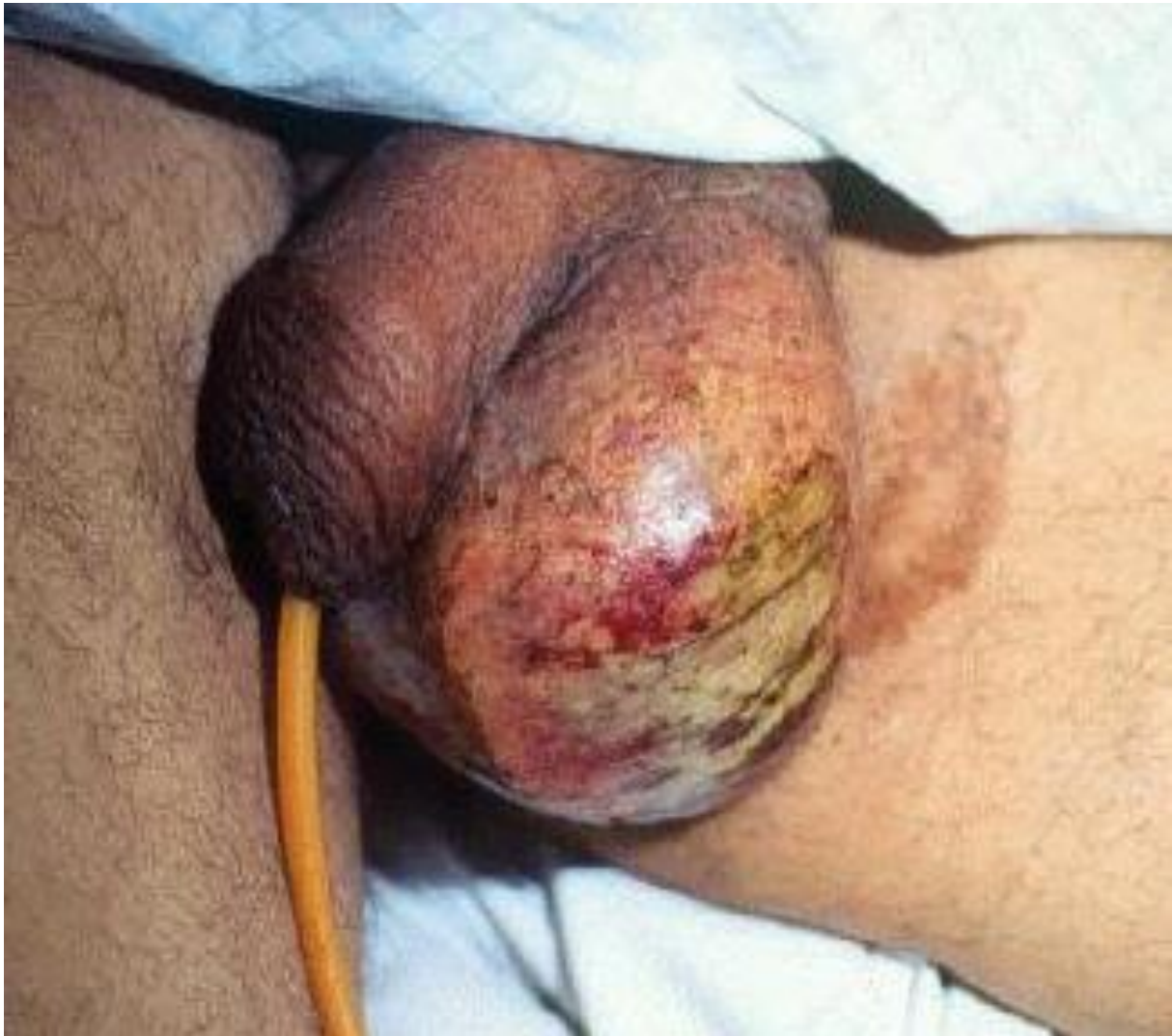**University Hospital, Geelong
Emergency Medicine
Trial Fellowship Exam
Short Answer Questions (SAQ)
Week 19**

PROP BOOKLET

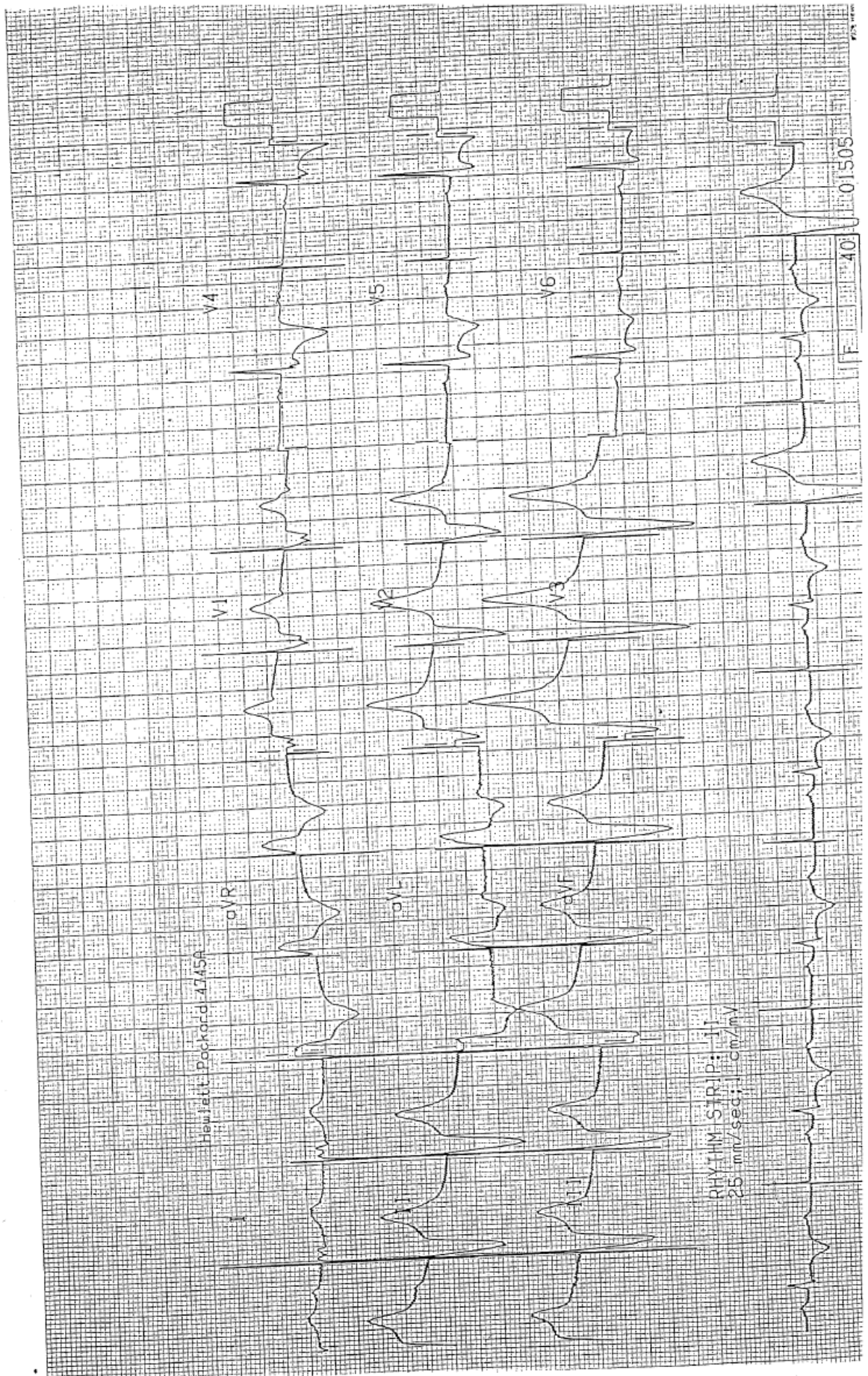
Question 1



Question 3

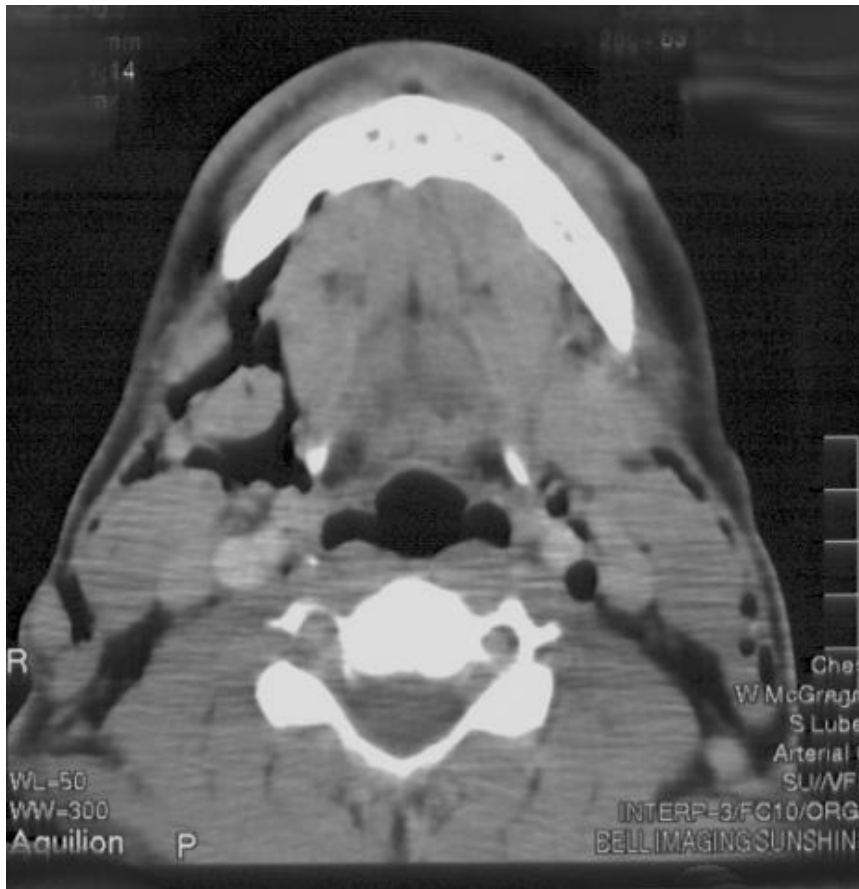

Question 5

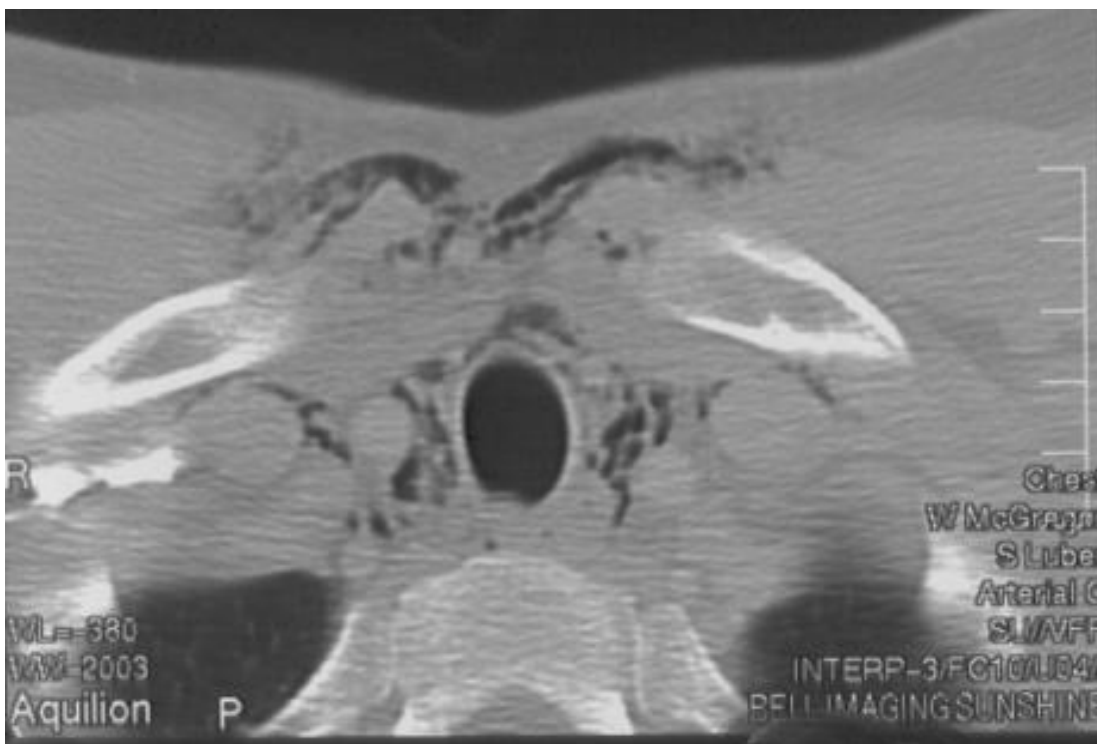

Question 6

1

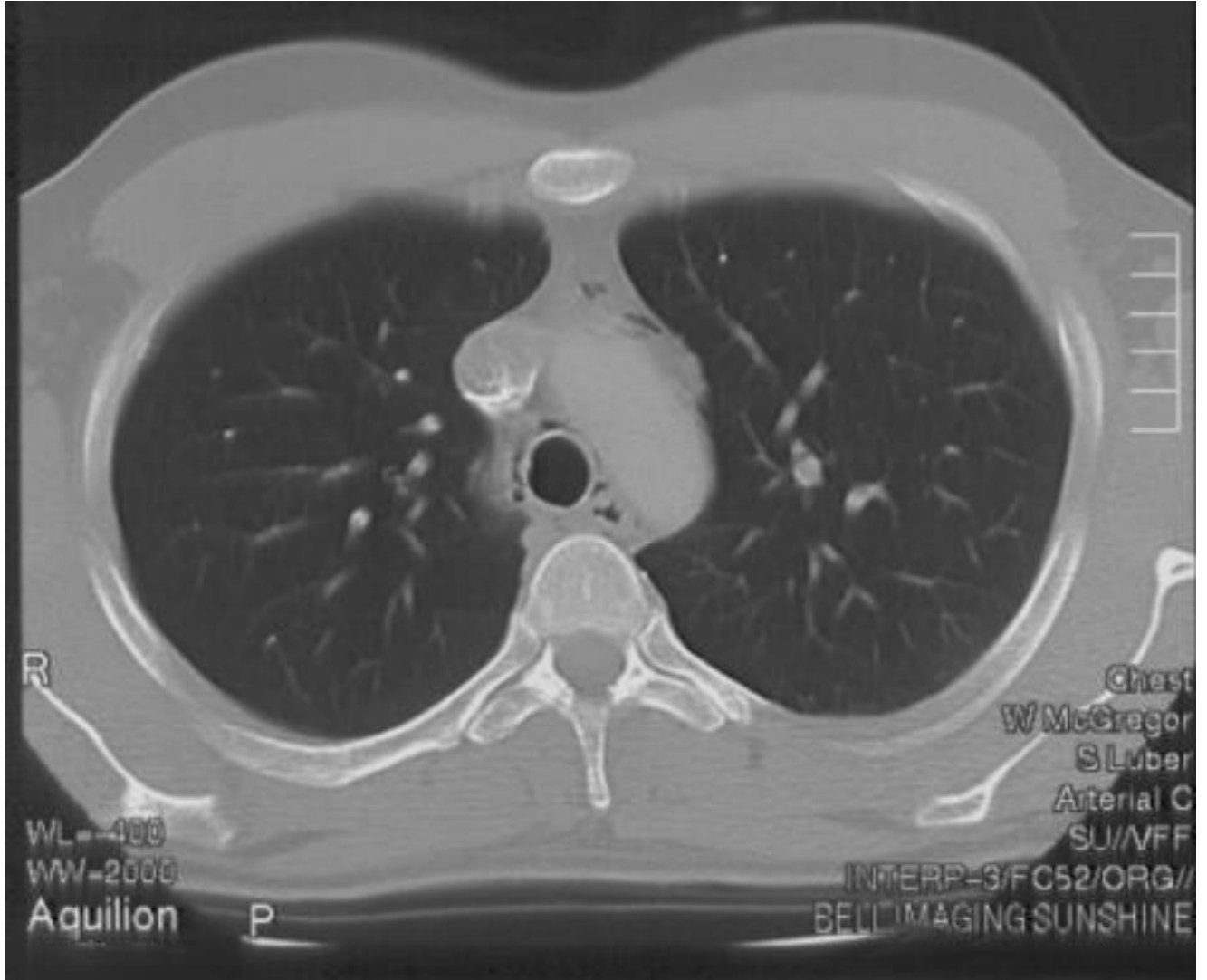


2



Question 6 continued

3

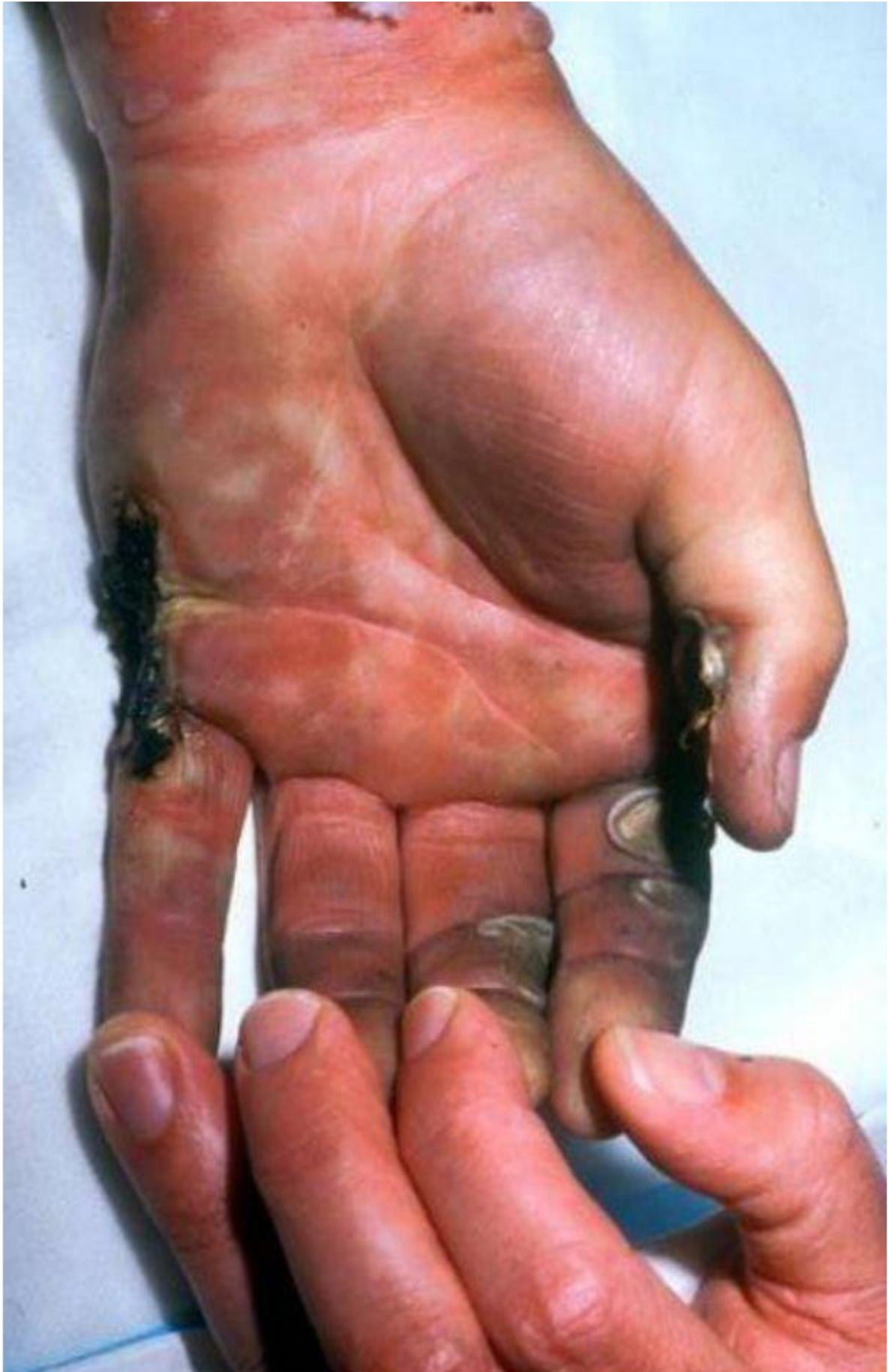

Question 7

Arterial blood gas and serum biochemical results.

			Reference Range
FIO ₂	0.5		
pH	7.62		(7.35-7.45)
pCO ₂	28.5	mmHg	(35-45)
pO ₂	234	mmHg	(80-95)
Bicarbonate	30.0	mmol/L	(22-28)
Base excess	8.3		(-3 - +3)
O ₂ saturation	99.8	%	(> 95)
Lactate	1.1	mmol/L	(< 1.3)
Na ⁺	131	mmol/L	(134-146)
K ⁺	2.0	mmol/L	(3.4-5)
Cl ⁻	90	mmol/L	(98-106)
Glucose	12.7	mmol/L	(3.5-5.5)

Question 9



"List" = 1-3 words

"State" = short statement/ phrase/ clause

**UNIVERSITY HOSPITAL, GEELONG
FELLOWSHIP WRITTEN EXAMINATION**

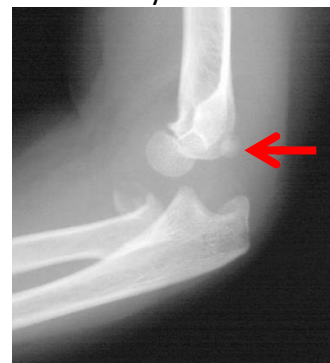WEEK 19– TRIAL SHORT ANSWER QUESTIONS Suggested answers

PLEASE LET TOM KNOW OF ANY ERRORS/ OTHER OPTIONS FOR ANSWERS

Please do not simply change this document - it is not the master copy !

Question 1 (18 marks)

A 10 year old girl presents to the emergency department after a fall from the monkey bars after school and complains of a painful elbow.



a. State four (4) abnormalities shown in this x-ray. (4 marks)

- **Posterior dislocation elbow - MANDATORY**
- **Radial head #- complete displacement- SH1- MANDATORY**
- **Medial epicondyle fracture - MANDATORY** (*You should not see the medial epicondyle on a true lateral/ common association with posterior elbow dislocation*)
- **Posterior fat pad (subtle)**
- **Soft tissue swelling**

After full assessment, the girl is confirmed to have this isolated injury. She is fasted. She has received no prehospital treatment. She does not currently have IV access.

b. List five (5) techniques for analgesia in the first 20 minutes of this presentation. (5 marks)

- **Immobilise in sling**
- **Distraction- TV/ Ipad**
- **N₂O**
- **I/N fentanyl 1- 1.5 mcg/kg**
- **IM ketamine- 1-2 mg/kg/ IV - 5- 10 mg aliquots**
- **IV (other arm) morphine 0.1 mg/kg bolus followed by 1 mg aliquots**

c. List four (4) indications for corrective treatment in the emergency department. (4 marks)

(OT is preferred given coexisting radial head and medial epicondyle)

- **N compromise**
- **A compromise**
- **Ongoing severe pain**
- **Significant delay to theatre**

An indication for urgent corrective treatment exists.

You attempt cannulation and fail 3 attempts. The patient's mother becomes very distressed and requests no further attempts at cannulation. She is verbally aggressive towards you. Corrective treatment is still required semi urgently.

State five (5) points to demonstrate how you would handle this situation. (5 marks)

(NB: corrective Rx still required)

- **Attempt verbal de-escalation including Apologise/ empathise**

University Hospital, Geelong- Fellowship Exam Short Answer Questions
Week 19

- **(If unable to be deescalated, consider utilising other senior staff to assist/ remove self)**
- **Explain consequences of delayed reduction- aiming for best outcome for the child**
- **Explain that IV will be required eventually**
- **Provide options to mother- eg IV placement after IM ketamine/ Nitrous/ gaseous induction**
- **Use option mutually agreed on above eg facilitate transfer to OT**

Question 2 (14 marks)

A 24 year old woman who is pregnant presents with per vaginal bleeding.

- a. Complete the table listing the suspected findings at the stated stage of pregnancy.(6 marks)

Stage of pregnancy	Quantative B HCG	Transvaginal ultrasound	Transabdominal ultrasound
<4 weeks	< 1000	-	-
5 weeks	> (1000-) 1500	Gestational sac	-
6 weeks	5000-20000	Foetal pole	Sac +/- pole
7 weeks	> (15000) 20000	Foetal heart/ cardiac activity	Pole +/- heart activity

NB: there is significant variability in reality- but approximate numbers should be known

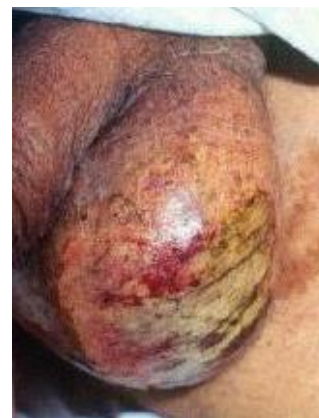- b. State three (3) specific findings on ultrasound that define a failure of pregnancy. (3 marks)

(NB not just "blighted ovum" without qualification what the findings are on US)

- **Sac > 10-12mm without a yolk sac**
- **Sac > (18-) 25 mm and no foetal pole**
- **Foetal pole or CRL \geq 7mm and no cardiac activity**

Question 3 (12 marks)

A 65 year old male presents with 4 days of scrotal pain.



- a. What is the diagnosis? (1 mark)
- **Fournier's gangrene**
 - (testicular abscess)
- b. State the significance of this condition? State three (3) points of significance. (3 marks)
- **Aggressive infection**
 - **Anaerobic and aerobic bugs**
 - **Usually secondary to perirectal disease or minor trauma**
 - **Needs aggressive Rx**
 - **Mortality high (40%)**
- c. List two (2) risk factors for the development of this condition? State two (2) points of significance. (2 marks)
- **Obesity**
 - **Immunocompromise:**
 - **DM**
 - **Alcoholism**
 - **Chronic steroid use**

Analgesia is provided. Disposition is arranged.

- d. List two (2) key treatment steps that you would institute in the first 20 minutes of your care. Provide one (1) justification for each choice. (4 marks)

Management task	Justification
Fluid resus	Aggressive
IV abs	Broad spectrum- meropenem + clindamycin + vancomycin
BSL stabilisation	Maximise wound healing Reduce additional systemic complications of hyperglycaemia

- e. List two (2) treatment methods that are utilised for definitive treatment. (2 marks)
- **Sx- early, aggressive debridement**
 - **Hyperbaric oxygen - adjunct to debridement (ie post)**

Question 4 (12 marks)

A 25 year old man is intubated for decreased conscious state following a polydrug overdose. The patient remains in your emergency department overnight. Following your ward round in the morning you assess the patient as being suitable for extubation.

- i) List four (4) patient factors that are required to allow safe extubation of this patient. (8 marks)

Patient factor (4 marks)	How would you ensure adequacy of each factor (4 marks)
Adequate spontaneous ventilation	<ul style="list-style-type: none"> • TV • ETCO₂ • ABG • No CXR / chest findings
Adequate oxygenation	<ul style="list-style-type: none"> • ABG- PaO₂ > 60 on FiO₂ < 40% • Low oxygen requirement •
Cardiac stability	<ul style="list-style-type: none"> • Stable rhythm • Stable obs • Vasopressors- absent or low dose • QRS within normal limits
Adequate conscious state	<ul style="list-style-type: none"> • sustained eye opening to verbal commands • No continuous sedative
Adequate strength/ NM blockade worn off	<ul style="list-style-type: none"> • Can lift head off pillow • Raise arms for 15 sec • Clap hands
Acid/ base state	<ul style="list-style-type: none"> • No significant acidosis

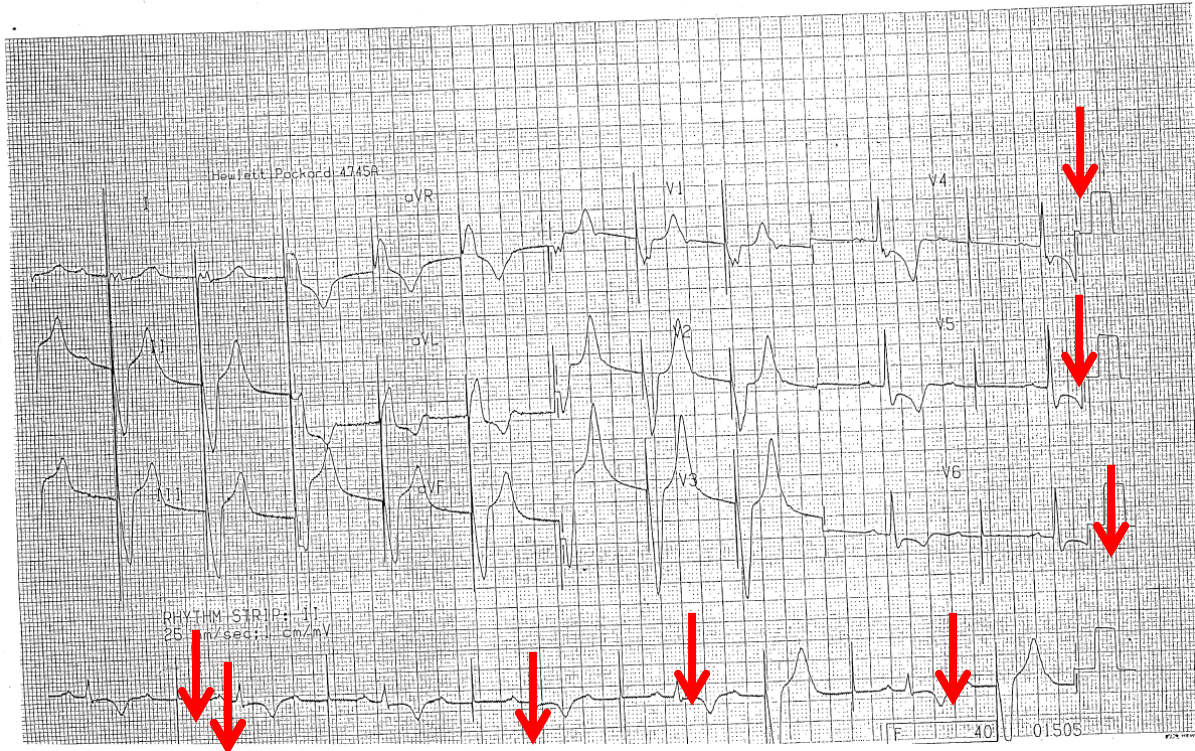
You successfully perform extubation.

- ii) List four (4) steps in your post- extubation care of this patient. (4 marks)
- **Re suction oropharynx**
 - **Assess adequacy of ventilation**
 - **L or R lateral position**
 - **Supplemental oxygenation**
 - **Do not leave patient until adequate ventilation confirmed**

Question 5 (11 marks)

A 75 year old man presents following a collapse.

- a. State five (5) abnormalities shown in this ECG. (5 marks)



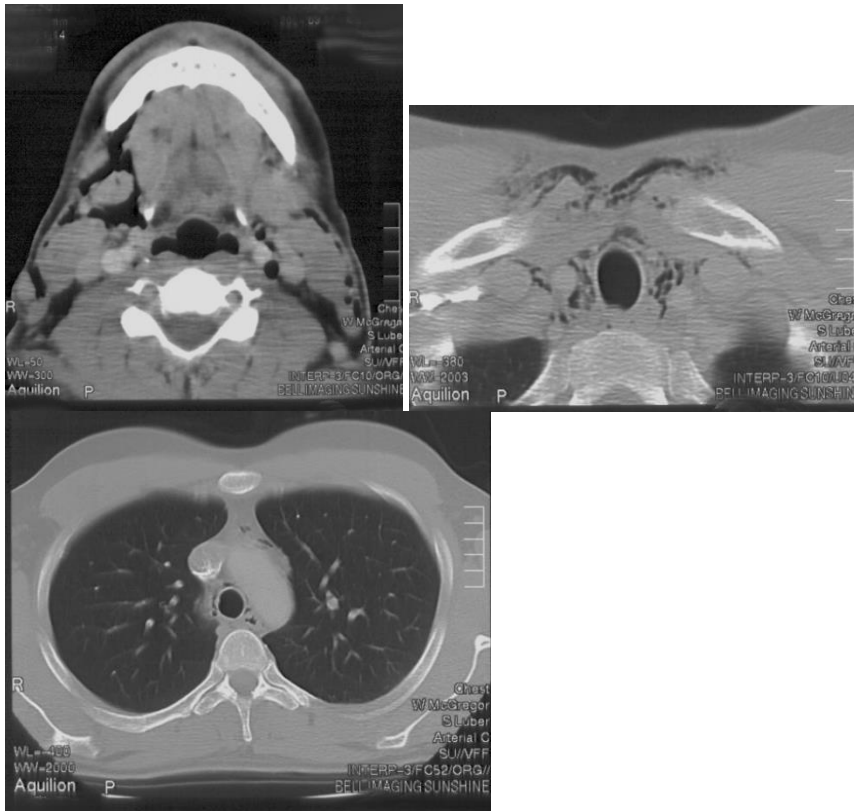- **Failure to capture**
 - **Sinus brady 45 bpm**
 - **STD in normal impulses in II**
 - **TWI in normal impulses in II**
 - **2nd degree HB with 2:1 conduction**
- (NB: Not failure to sense or failure to pace)

- b. List six (6) possible causes for this ECG problem. (6 marks)

- **electrode tip out of position**
- **pacemaker voltage too low or battery dead**
- **lead wire broken**
- **oedema or scar tissue at electrode tip**
- **myocardial perforation by lead wire**
- **myocardial infarction/ischaemia at lead wire**
- **hyperkalaemia**

Question 6 (12 marks)

A 35 year old man presents with right sided facial swelling 24 hours after bilateral wisdom tooth removal.



1 mark for finding, 1 mark for adequate description of the site of the abnormality

- State two (2) abnormal findings in the CT scan labelled 1 (2 marks)
 - Extensive surgical emphysema**
 - Within soft tissue planes between muscular & vascular structures in R> L side of neck**
- State two (2) abnormal findings in the CT scan labelled 2 (2 marks)
 - Subcutaneous surgical emphysema & gas**
 - Anteriorly & lateral to upper trachea (no compression)**
- State two (2) abnormal findings in the CT scan labelled 3. (2 marks)
 - Pneumomediastinum**
 - small amount gas around trachea & anterior to arch of aorta**
- List six (6) possible complications of this condition. (6 marks)
Need 2 underlined to get > 2 (ie max 2/4 if these are not both mentioned)
 - Pain- 2° to subcutaneous air & thus pressure on tissues**
 - Disfigurement- facial, neck swelling- temporary**
 - Deep seated infection- pharyngeal abscess**
mediastinitis- potentially life threatening → spread to lungs, heart
 - Pressure from subcutaneous air- airway compromise, compression of major airways/ aorta, potentially heart via pneumopericardium & ∴ heart failure**

University Hospital, Geelong- Fellowship Exam Short Answer Questions
Week 19

- **Gas embolism- unlikely to occur in delayed setting**

NB: *Death- from this condition is very unlikely*

Also acceptable:

- **Loss of income for patient dt hospitalisation/ convalescent period**
- **Hospital acquired conditions-** pneumonia
DVT from immobilisation
IV site phlebitis
drug allergy (*eg. Ab's*)

Click on the image below to view the entire PDF (& print/save if necessary)

Emergency Medicine Australasia (2004) 16, 244–246

CASE REPORT



Extensive surgical emphysema following restorative dental treatment

Peter Aquilina and Geoffrey McKellar
Department of Oral and Maxillofacial Surgery, Westmead Hospital, Sydney, New South Wales, Australia

Abstract

We present a patient with extensive surgical emphysema following the dental restoration of the upper left first molar (tooth 26) with a high speed turbine handpiece. The clinical findings and management of subcutaneous cervical emphysema are discussed.

Key words: *dental treatment, subcutaneous cervical emphysema.*

Introduction

A 31-year-old woman was referred to the Emergency Department of Westmead Hospital by her general dental practitioner (GDP) following the acute onset of left periorbital and facial swelling during the dental restoration of the upper left first molar (tooth 26). After obtaining local anaesthesia by infiltrating 2 mL of 2% lignocaine and adrenaline 1:100 000 into the buccal sulcus, the cavity preparation proceeded uneventfully until rapid facial swelling occurred towards the end of the procedure. Her GDP ceased further work and referred her to the ED.

On examination, a well looking woman with obvious left facial swelling was seen (Fig. 1). Her vital signs were all within normal limits (temperature 37.1°C, respiratory rate 16 breaths per minute, heart rate 80 beats per minute, blood pressure 120/70 mmHg) and she was warm and well perfused.

Examination of her respiratory and cardiovascular system revealed vesicular breath sounds with good air entry bibasally and a midline trachea. She was able to swallow and was not in any respiratory distress. The

apex beat was located in the midclavicular line at the 5th intercostal space and the heart sounds were dual with no added sounds.

Palpation of the swollen areas of the patient's face elicited crepitus. There was some tenderness on palpation of the left sternocleidomastoid muscle and she had trismus with a maximal interincisal opening distance of 25 mm. The patient was reluctant to rotate her head to the contralateral side of the swelling as this elicited pain in the left sternocleidomastoid muscle.

Intraoral examination revealed a small laceration in the depths of the upper left buccal vestibule adjacent to tooth 26 and measuring approximately 5 mm in length. The wound was not gaping and did not require repair. The remainder of her intraoral examination was normal and in particular there was no swelling or distortion of the posterior or lateral pharyngeal walls and the uvula was located in the midline with no deviation.

Radiographic examination included posteroanterior and lateral chest films and a CT study of her face and neck. The chest films were unremarkable, however, the CT scan of her face and neck showed extensive surgical emphysema extending into the left infratemporal fossa

Correspondence: Dr Peter Aquilina, Department of Oral and Maxillofacial Surgery, Westmead Hospital, Sydney, Australia. Email: peteraquilina@optusnet.com.au

Peter Aquilina, MBBS (Hons), BDS (Hons), FRACDS, FRACDS (OMS) Visiting Medical Officer, Department of Oral and Maxillofacial Surgery; Geoffrey McKellar, BDS, MDS, FRACDS, FRACDS (OMS), Clinical Associate Professor and Director.

Conflicts of interest: None

Question 7 (11 marks)

A 74 year old man is brought to your emergency department with 1 week of shortness of breath and chest pain.

His observations are:

HR 110 /min
BP 135/870 mmHg supine
Temperature 38 °C

Arterial blood gas and serum biochemical results.

			Reference Range
FIO ₂	0.5		
pH	7.62		(7.35-7.45)
pCO ₂	28.5	mmHg	(35-45)
pO ₂	234	mmHg	(80-95)
Bicarbonate	30.0	mmol/L	(22-28)
Base excess	8.3		(-3 - +3)
O ₂ saturation	99.8	%	(> 95)
Lactate	1.1	mmol/L	(< 1.3)
Na ⁺	131	mmol/L	(134-146)
K ⁺	2.0	mmol/L	(3.4-5)
Cl ⁻	90	mmol/L	(98-106)
Glucose	12.7	mmol/L	(3.5-5.5)

- a. Provide two (2) calculations to help you to interpret these results. State the significance of each finding.(2 marks)
- Derived value 1: **A-a gradient= 91**
 - Significance: **VQ mismatch or R-L shunt exists**
 - Derived value 2: **Expected PCo₂ = 0.9 x HCO₃ +9 = 0.9 x30 +9 = 36**
 - Significance: **concomitant respiratory alkalosis exists in addition to metabolic alkalosis**
- b. Using the scenario and the derived values, define the primary acid/base abnormality/s. (2 marks)
- **Hypochloraemic, metabolic alkalosis**
 - **Respiratory alkalosis**
- c. List five (5) likely unifying explanation for these gases in this clinical context. (5 marks)
- **Raised Aa gradient:**
 - **Pneumonia**
 - **PE**
 - **COPD- infective exacerbation**
 - **Asthma**
 - **Pneumothorax**
 - **Boorhaaves**
 - **Interstitial lung disease + infection**

University Hospital, Geelong- Fellowship Exam Short Answer Questions
Week 19

- **Vomiting**
 - **Secondary to sepsis**
 - **Secondary to antibiotics**
 - **Secondary to codeine/tramadol/oxycodone for pain**

Question 8 (12 marks)

A 65 year old man presents with a headache. He has not experienced trauma prior to the headache onset.

His observations are:

HR	90	/min
BP	255/150	mmHg supine
Temperature	37°C	

- a. Other than phaeochromocytoma and idiopathic hypertension, list six (6) likely underlying causes for his hypertension. (6 marks)
- **SOL eg tumour**
 - **Stroke- ischaemic or SAH**
 - **Toxic- eg Methamphetamines**
 - **Sudden withdrawal of AntiHT**
 - **Renal artery stenosis**
 - **Cushings/ Conns syndrome**
 - **Extreme pain/ anxiety**

You have a strong suspicion of the diagnosis of phaeochromocytoma.

- b. List your preferred drug regime to treat the blood pressure in this setting (doses are not required). (3 marks)
- **IV morphine**
 - **IV phentolamine**
 - **+/- nitroprusside**
 - **B blockers only after α blockade**
- c. List three (3) investigations that may be performed to assist in confirmation of the diagnosis of phaeochromocytoma. (3 marks)
- **Urinary catecholamines/ metabolites**
 - **Plasma free metanephrine**
 - **(123 metaiodobenzlguanidine scan)**
 - **CT/ MRI to localise tumour**

This resource is produced for the use of University Hospital, Geelong Emergency staff for preparation for the Emergency Medicine Fellowship written exam. All care has been taken to ensure accurate and up to date content. Please contact me with any suggestions, concerns or questions.

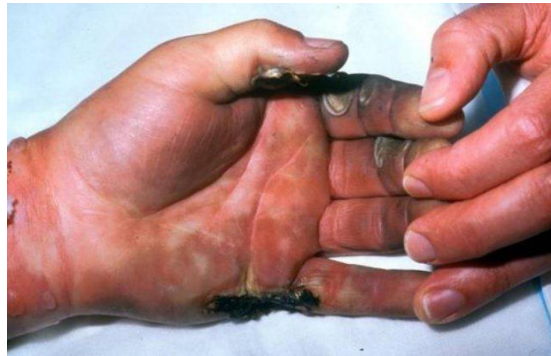Dr Tom Reade (Staff Specialist, University Hospital, Geelong Emergency Department)

Email: tomre@barwonhealth.org.au

November 2017

Question 9 (18 marks)

A 35 year old man presents to your emergency department after a high voltage electrical injury.



- a. State four (4) features of this photograph that suggest a significant injury. (4 marks)
- **Finger involvement**
 - **Tissue loss- deep tissue involvement**
 - **Discolouration of burn- white/black- suggesting full thickness burn**
 - **Mottling of hand- suggesting thrombosis**
- b. List six (6) systemic/ distant complications from the passage of high current through the body.(6 marks)
- **Colonic ischaemia**
 - **Pancreatitis**
 - **Bone ischaemia**
 - **GBitis**
 - **Small bowel ischaemia**
 - **Vascular spasm & thrombosis**
 - **Rhabdomyolysis**
 - **Death**
- c. What is the role of the presenting ECG in household (240V) electrical exposure? State 2 points in your answer (2 marks)
- **Patients without ECG changes on presentation are unlikely to experience life threatening arrhythmias**
 - **ECG changes mandates further monitoring**
- d. List six (6) indications for ongoing ECG monitoring following an electrical exposure. (6 marks)
- **ECG changes**
 - **Documented arrhythmias**
 - **High voltage (> 1000V)**
 - **Loss of consciousness**
 - **Seizure**
 - **Previous cardiac disease (especially arrhythmias)**
 - **Troponin rise**