Cardiovascular SAQs

Emergency Medicine Fellowship Program

How to use this book:

1) Complete SAQs

- < 3 months until exam: Exam conditions – focus on clear answers 'to time'
- 3-6 months until exam: Transition towards exam conditions
- > 6 months until exam: Open book is ok, 'focus on good answers and developing knowledge acquisition

2) Read and study around SAQ

- Use each SAQ as motivation to study around the individual topic
- Think about the different ways the topic could come up in the SAQ exam (use the topic structure provided by APEM course)

3) Write SAQs to further develop this program

- Review syllabus of medical expertise
- Create SAQs relating to topics not covered in this book, please format to be in exam-format, include answers
- This will help further develop this program as well as help you think like an examiner
- Return to ben.shepherd86@gmail.com

ALL THE BEST!

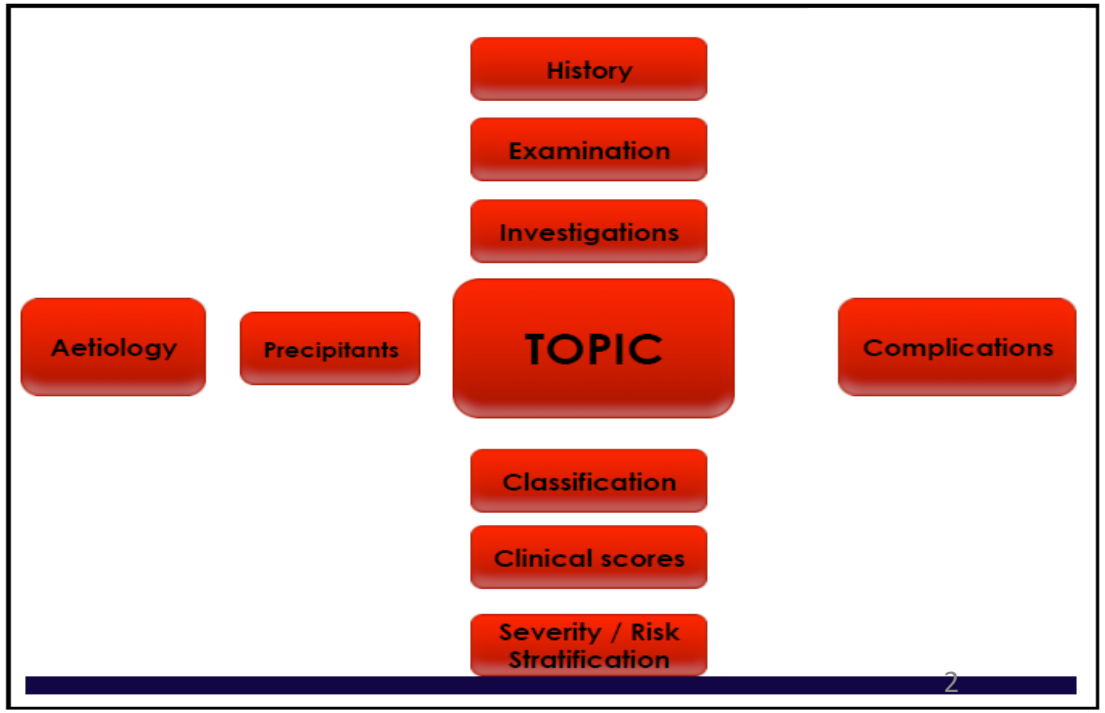

3.1 Cardiovascular

a) Clinical examination of the cardiovascular system E H
b) Interpretation of symptoms and clinical signs of the cardiovascular system E Ex
c) Acute coronary syndromes (ACS)
    i) Approach to the patient with chest pain DIS Ex
    ii) Prehospital management S H
    iii) Low-risk chest pain I/S H
    iv) Stable angina DIS H
    v) Unstable angina DIS H
    vi) Myocardial infarction DIS Ex
    vii) Right ventricular myocardial infarction DIS H
    viii) Thrombolysis in myocardial infarction M Ex
    ix) Left ventricular failure and cardiogenic shock in the setting of myocardial infarction DIS H
    x) Interventional cardiology in acute coronary syndromes M/P G
    xi) Pharmacological agents used in acute coronary syndromes D H
    xii) Interpreting the ECG in the setting of acute coronary syndromes I Ex
    xiii) ST elevation in the absence of myocardial infarction I Ex
    xiv) An understanding of the major trials in acute coronary syndromes T H
    xv) Current research in ACS T H
    xvi) Chest pain pathways M/S H
    xvii) Chest pain units M/S H
d) Syncope DIS H
    i) Differential diagnosis
    ii) Identification of at-risk groups
    iii) Management and disposition
e) Congestive cardiac failure DIS H
f) Valvular disorders
    i) Aortic DIS H
    ii) Mitral DIS H
    iii) Tricuspid DIS G
    iv) Pulmonary DIS G
    v) Conditions that are associated with valvular disorders DIS G
g) Disorders of the myocardium
    i) Cardiomyopathy DIS G
    ii) Aneurysm DIS G
    iii) Atrial septal defect DIS G
    iv) Ventricular septal defect DIS G
    v) Dextrocardia DIS G
h) Disorders of the pericardium
    i) Acute pericarditis DIS H
    ii) Constrictive pericarditis DIS G
    iii) Pericardial effusion DIS G
    iv) Pericardial tamponade DIS H
    v) Pericardiocentesis P H
i) Cardiogenic shock DIS H
j) Hypertension
    i) Urgencies DIS H
    ii) Emergencies DIS Ex
    iii) Pharmacological agents used to treat hypertension D H
k) Disturbances of cardiac rhythm
    i) Mechanisms of arrhythmias T H
    ii) Bradycardias
        i. sinus bradycardia DIS Ex
        ii. heart block DIS Ex
        iii. other bradycardias DIS Ex
    iii) Tachycardias DIS Ex
        i. narrow complex regular DIS Ex
        ii. narrow complex irregular DIS Ex
        iii. wide complex regular DIS Ex
        iv. wide complex irregular DIS Ex
        v. torsade des pointes DIS Ex
        vi. ventricular fibrillation DIS Ex
    iv) Ectopy
        i. narrow complex DIS Ex
        ii. wide complex DIS Ex
    v) Accessory pathways
        i. Wolff-Parkinson-White syndrome DIS Ex
        ii. other DIS H
    vi) Electrophysiological testing I G
    vii) Drugs associated with cardiac arrhythmias D Ex
    viii) Pharmacological agents used to treat arrhythmias D Ex
    ix) International guidelines for the management of arrhythmias D Ex
l) Implantable cardiac devices (ICDs)
    i) Implantable pacemakers Eq G
    ii) Implantable defibrillators Eq G
    iii) Complications of ICDs Eq/T G
m) External and internal emergent cardiac pacing Eq/P H
n) Disorders of the peripheral vasculature
    i) Deep venous thrombosis DIS H
    ii) Pulmonary embolism DIS H
    iii) Mesenteric ischaemia DIS H
o) Cardiac transplantation DIS G
p) Endocarditis DIS H
q) Tumours DIS G
r) Congential heart disease DIS G
i) Cyanotic heart disease DIS H
s) Rheumatic fever DIS H

Column "LO" – Categories of Learning Objectives			Column "LP" – Levels of Practice
DIS - Diseases/Injuries/Symptoms	D - Pharmacological & toxicological agents		Ex - Expert
E - Physical Examination	P - Procedures	S - Systems	H - High
I - Investigations	Eq - Equipment	NCI - Non-clinical/clinical interface	G - General
M - Medical Interventions	T - Theories		

A 47 year old lady presented to the emergency department with syncope and altered conscious state. She has a past medical history of hypertension, paroxysmal atrial fibrillation and depression.

Her observations in the emergency department are as follows:

GCS	14	(E3, V5, M6)
BP	60/40	mmHg

An ECG is taken on arrival and shown on the page opposite.

1. Describe her ECG giving three (3) positive and two (2) relevant negative findings

2. Describe four (4) different steps you would take to treat her hypotension.

3. List two (2) pros and two (2) cons of using activated charcoal for this patient.

aVR
V1
V4
I
aVL
V2
V5
III
aVF
V3
V6
II
150 Hz
25.0 mm/s
10.0 mm/mV
4 by 2.5s + 1 rhythm ld
MAC5K 001B
12SL™v252

A 45 year old man presents with vague symptoms of central dull chest pain and mild shortness of breath on exertion for the past 3 days.

His observations are:

Temperature	37	°C
BP	120/70	mmHg
RR	18	/min
O_2 saturations	99%	on room air

An ECG is taken and is shown on the opposite page

1. Interpret his ECG giving three (3) positive findings.

2. List four (4) differential diagnoses for this appearance on the ECG.

3. List three (3) features on assessment that would determine disposition.

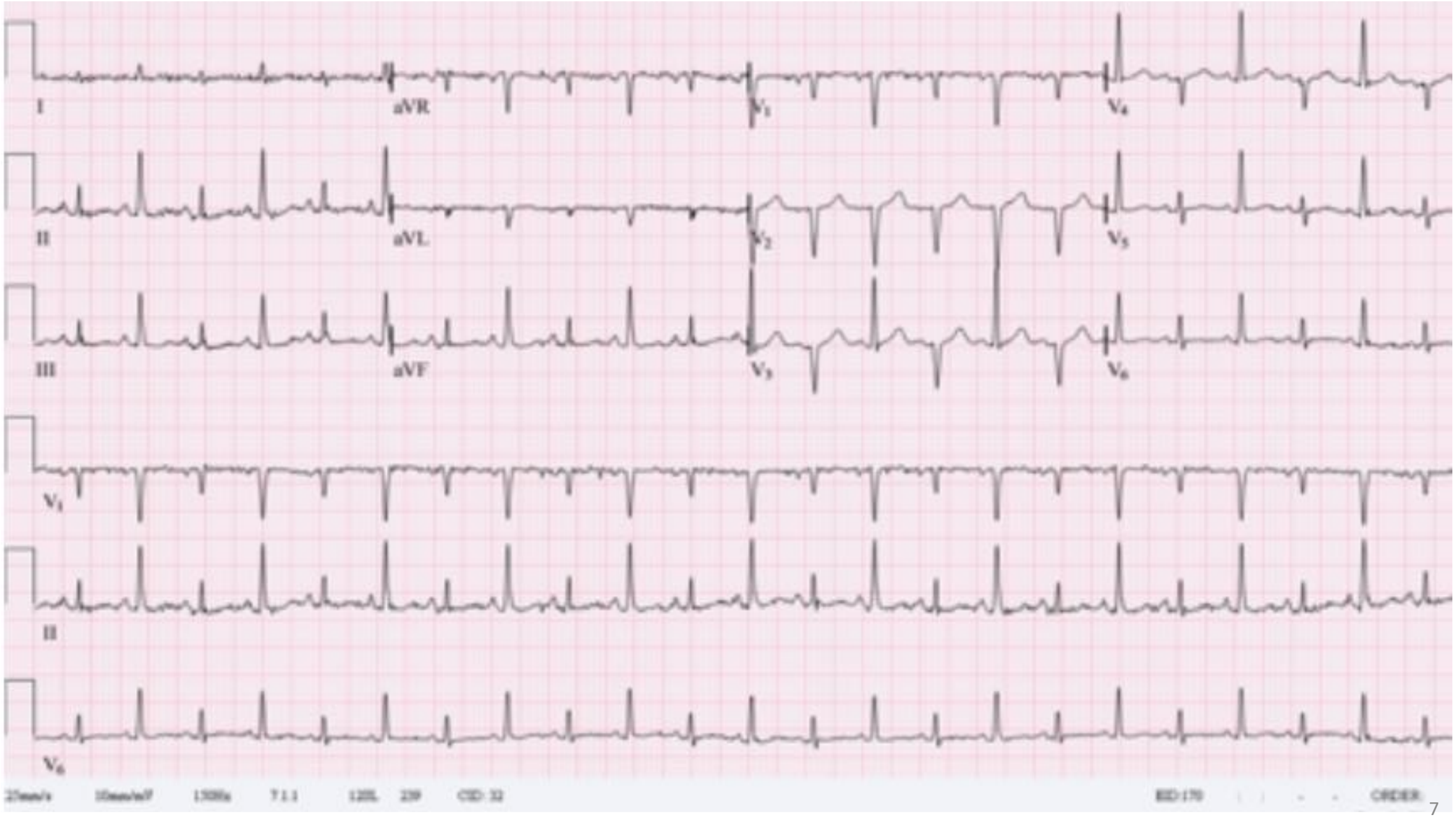
I
aVR
V1
V4
II
aVL
V2
V5
III
aVF
V3
V6
V1
II
V6

A 13 year old boy has a syncopal episode while playing sport. There was no trauma. He is unconscious for one minute and there is no seizure activity during this time, nor evidence of a post-ictal phase.

His observations are as follows:

BP	105/70	mmHg
HR	90	/min
RR	18	/min
O_2 saturations	99%	on room air
GCS	15	

An ECG is done and is shown on the page opposite.

1. List four (4) relevant findings on the ECG.

2. What is the diagnosis?

3. List two (2) of the most important complications associated with this diagnosis.

4. List three (3) important management priorities during this current admission.

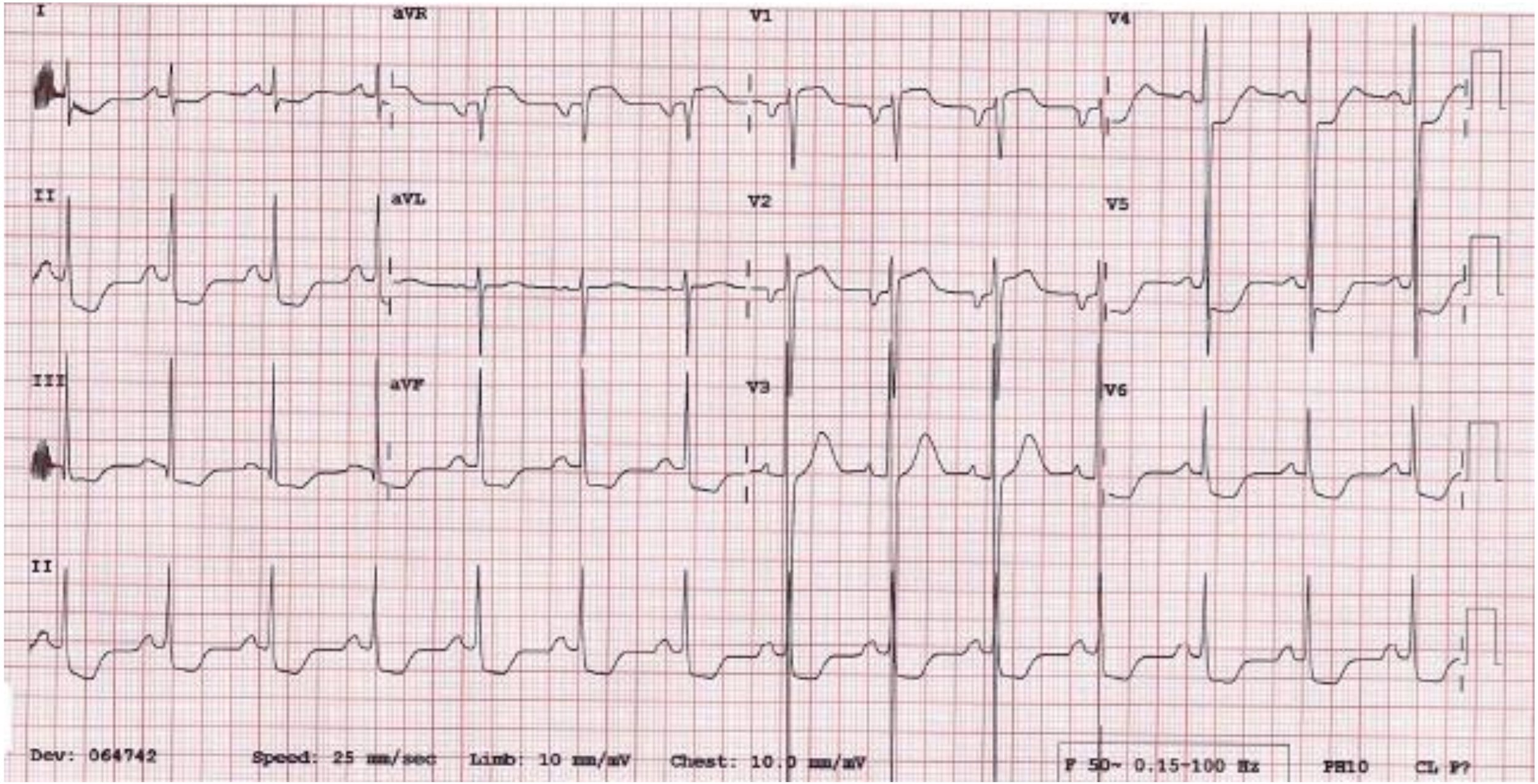
I
aVR
V1
V4
II
aVL
V2
V5
III
aVF
V3
V6
II
Dev: 064742
Speed: 25 mm/sec
Limb: 10 mm/mV
Chest: 10.0 mm/mV
F 50~ 0.15-100 Hz
PH10
CL P?

You are the consultant in charge of a tertiary emergency department. It is 9pm on a Saturday night. The ambulance service notifies you of a patient that is 20 minutes away with severe chest pain. He is a 53 year old man who has had pain for 3 hours unresponsive to simple analgesia, but is otherwise haemodynamically normal. The ambulance crew have faxed an ECG to you.

The ECG is shown in the prop booklet supplied - page 6.

i. Give one (1) positive and two (2) negative findings on the ECG. Give a single unifying diagnosis.

1 _____

2 _____

3 _____

Unifying diagnosis: _____

On arrival the patient presents acutely short of breath with crackles to his midzones. His observations are as follows:

HR	60	beats/min
BP	85/65	mmHg
SaO_2	85%	on 15L via Hudson mask

ii. List your six (6) immediate management steps.

1 _____

2 _____

3 _____

4 _____

5 _____

6 _____

iii. List four (4) drugs you would use to safely intubate this patient. Provide doses and intervals between each drug.

	Drug	Dose	Timing
1			
2			
3			
4			

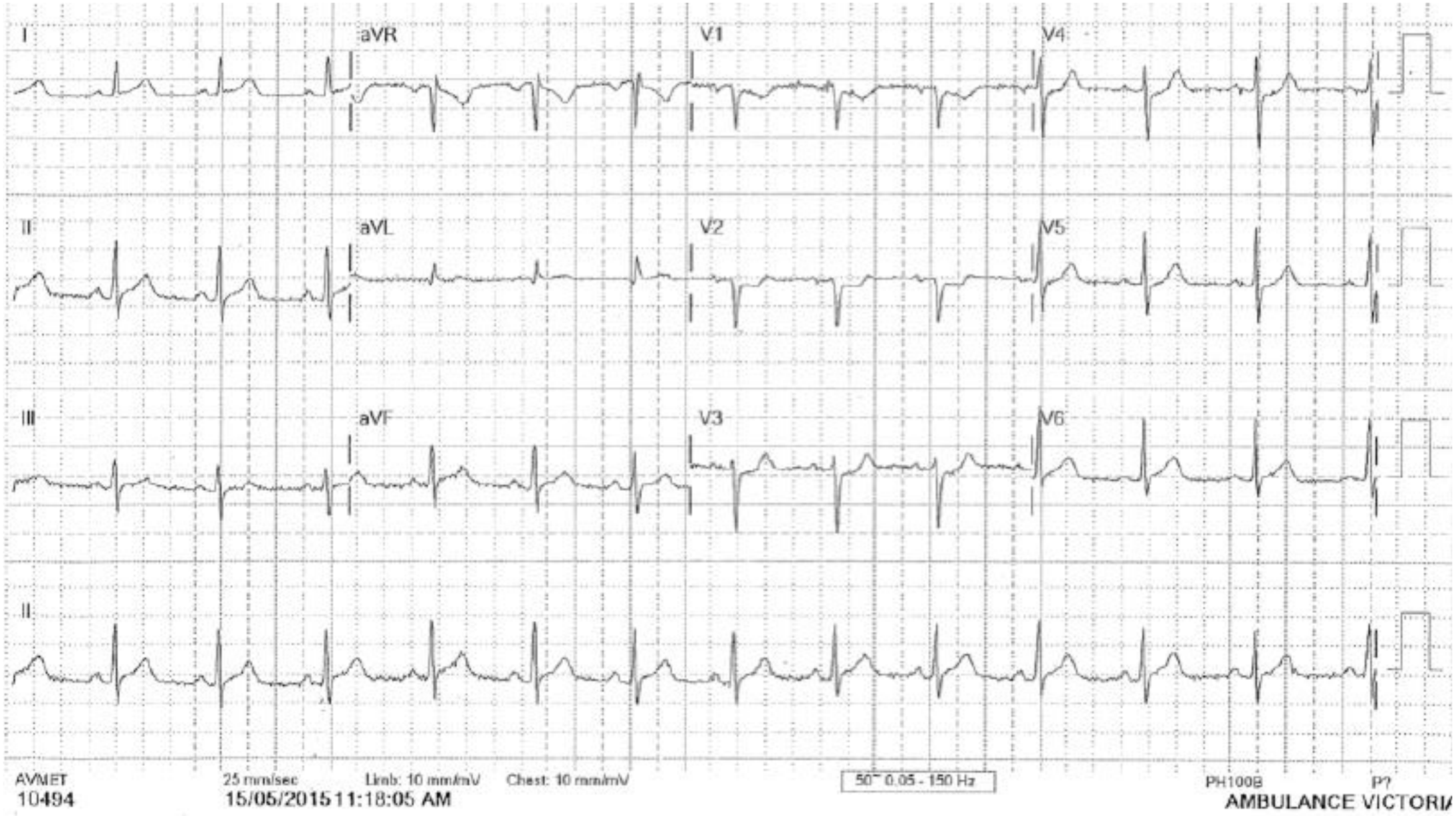
I
aVR
V1
V4
II
aVL
V2
V5
III
aVF
V3
V6
II
AVMET
10494
25 mm/sec
Limb: 10 mm/mV
Chest: 10 mm/mV
50~ 0.05 - 150 Hz
PH100B
P?
15/05/2015 11:18:05 AM
AMBULANCE VICTORI

A 23 year old man presents to the Emergency Department after feeling palpitations at home. He has had similar symptoms previously but has never been investigated. He is now feeling completely well.
His BP is 120/70 mmHg and all other observations are normal.

An ECG is taken and is shown in the props booklet provided - page 14.

i. Interpret his ECG giving three (3) positive and two (2) relevant negative findings.

1 _____

2 _____

3 _____

4 _____

5 _____

ii. List three (3) differential diagnoses

1 _____

2 _____

3 _____

iii. List five (5) relevant investigations and provide a justification for each

	Investigation	Justification
1		
2		
3		
4		
5		

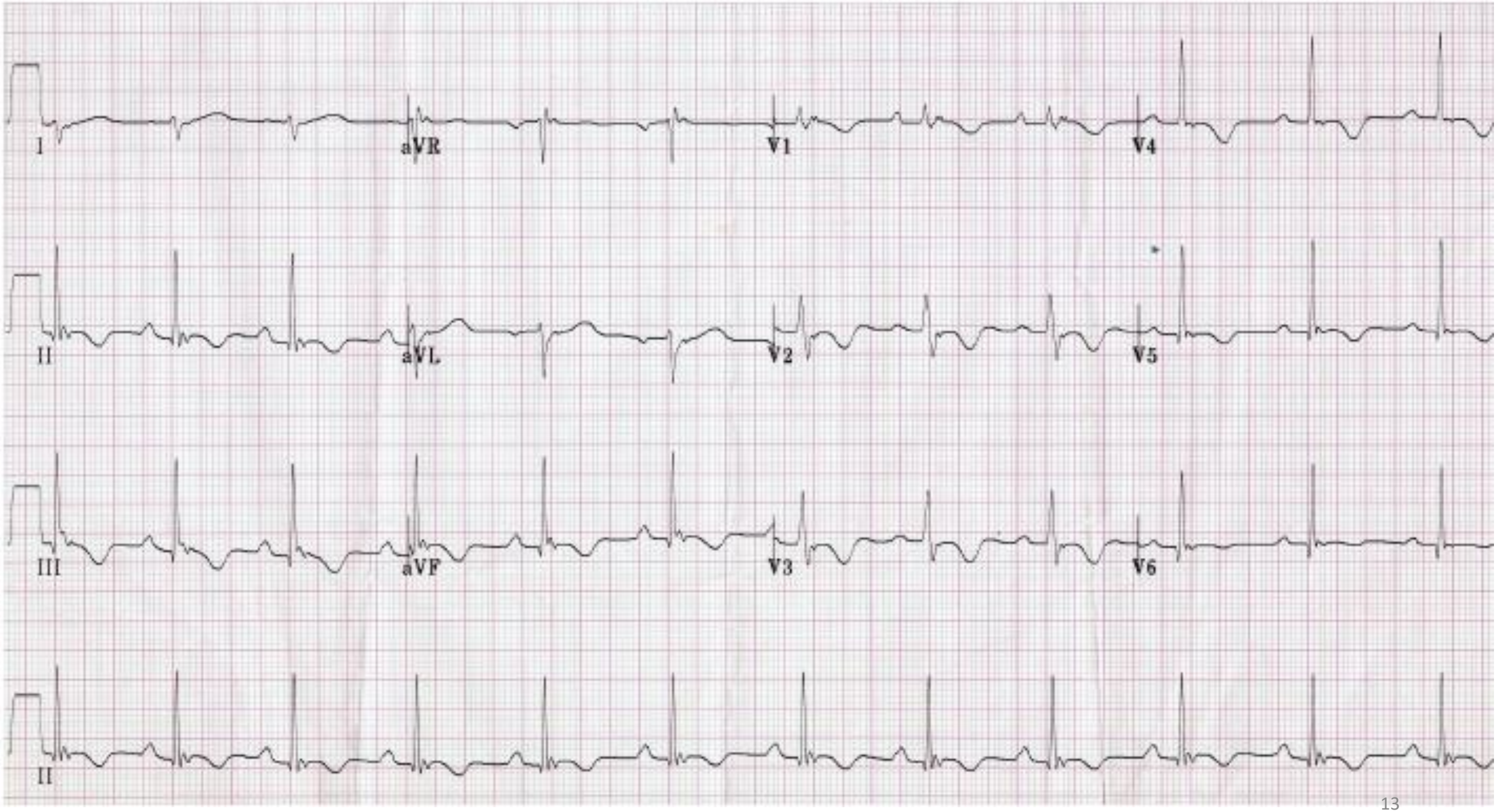
I
aVR
V1
V4
II
aVL
V2
V5
III
aVF
V3
V6
II

Shortly after presentation to the Emergency Department the patient complains of palpitations.

His observations are as follows:

BP	90/50	mmHg
O2 sats	96%	on room air
GCS	15	(E4, V5, M6)

His ECG is shown in the props booklet provided - page 15.

i. Provide five (5) relevant findings on the ECG and one unifying diagnosis

1 _____

2 _____

3 _____

4 _____

5 _____

Unifying diagnosis:_____

ii. Describe six (6) steps that you would perform to cardiovert this patient. List them in the order which you would perform them. Give drugs and doses where appropriate.

1 _____

2 _____

3 _____

4 _____

5 _____

6 _____

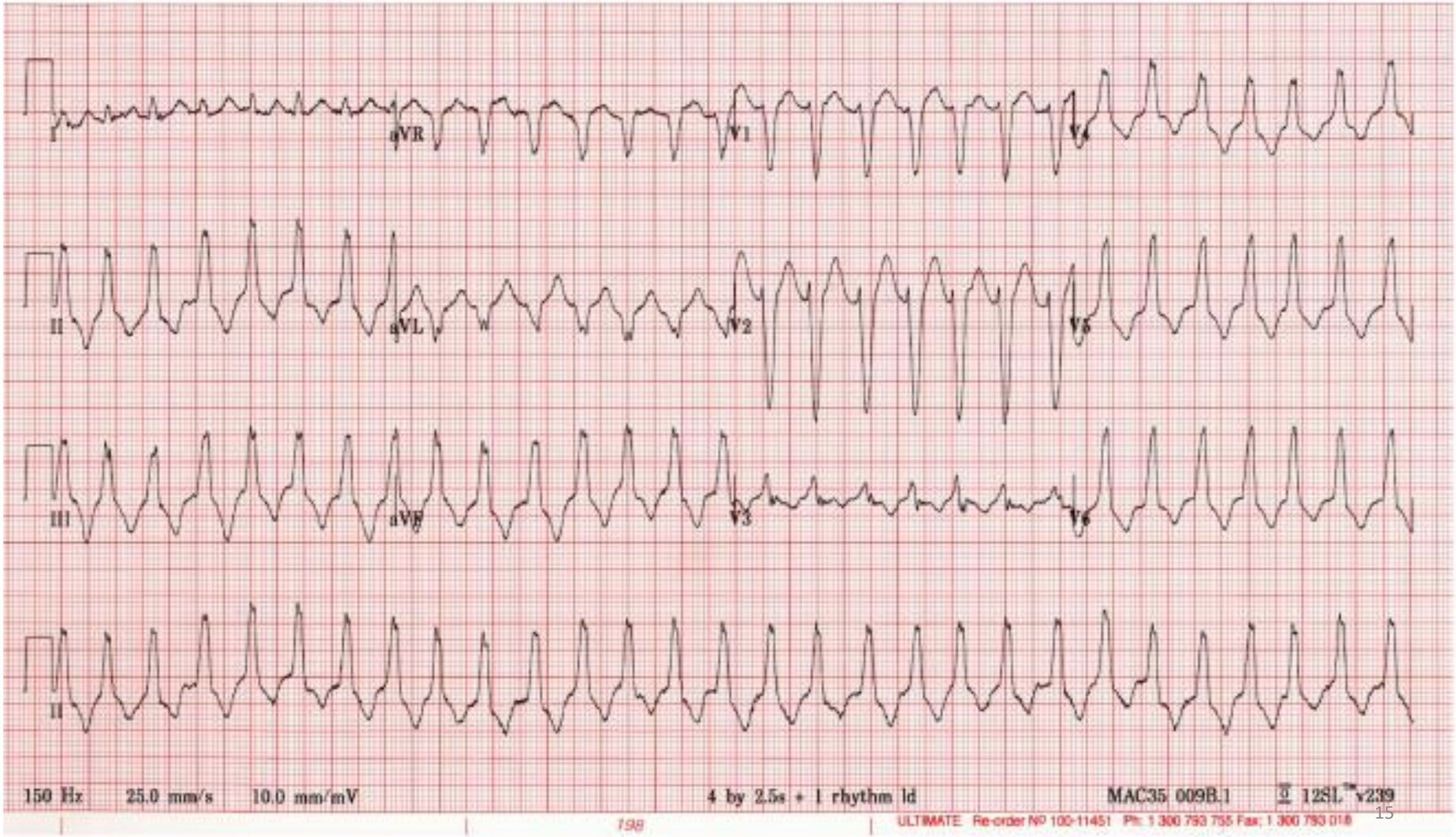
I
aVR
V1
V4
II
aVL
V2
V5
III
aVF
V3
V6
II
150 Hz
25.0 mm/s
10.0 mm/mV
4 by 2.5s + 1 rhythm ld
MAC35 009B.1
12SL™v239
ULTIMATE Re-order № 100-11451 Ph: 1 300 793 755 Fax: 1 300 793 018

A 17 year old male presents after an episode of syncope while out running. He is currently asymptomatic.
On examination you hear a systolic murmur. His observations are as follows:

HR	60	/min
BP	130/80	mmHg
Temp	36.8	ºC
GCS	15	

i. Complete the following stating what happens to the systolic murmurs in the table with the described manoeuvres. (12 marks)

Manouevre	**Lesion**			
	Hypertrophic cardiomyopathy (3 marks)	**Mitral valve prolapse** (3 marks)	**Aortic stenosis** (3 marks)	**Mitral regurgitation** (3 marks)
Valsalva				
Squatting				
Hand grip				

ii. You suspect Hypertrophic cardiomyopathy. List three (3) features that may be present on the ECG of a patient with Hypertrophic cardiomyopathy. (3 marks)

1 _____

2 _____

3 _____

iii. In a patient with confirmed Hypertrophic Cardiomyopathy, list three (3) specific treatments that may prevent sudden death? (3 marks)

1 _____

2 _____

3 _____

A 70 year old man present with shortness of breath and dizziness. He has a past medical history of ischaemic heart disease, AF, and high cholesterol. His medications are metoprolol, rivaroxiban and atorvastatin.

On examination his observations are as follows:

HR	100	/min AF
BP	90/50	mmHg
Temp	37.8	ºC
Sats	96%	on 8L O_2 via Hudson mask

i. Label the subxiphoid ultrasound image below. (4 marks)

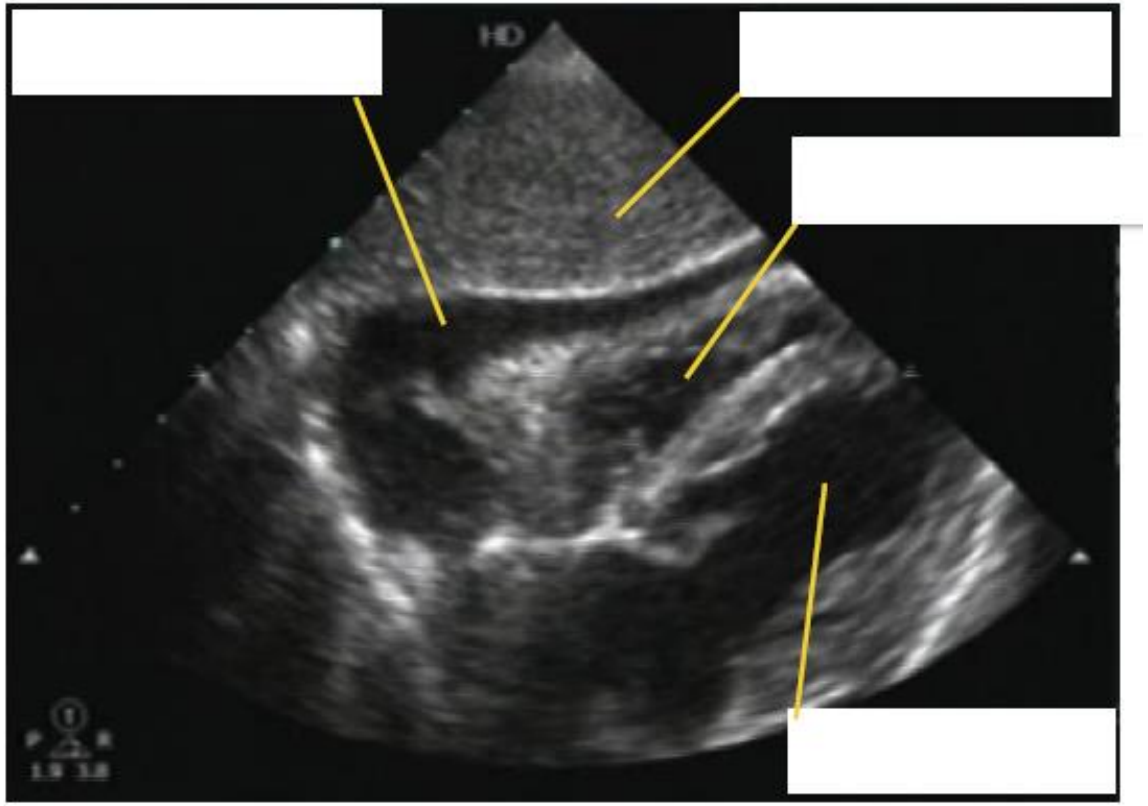

ii. In the table below list 6 categories of differential diagnosis for the underlying cause and give 2 examples of each. (18 marks)

	Category (6 marks)	Examples (12 marks)
1		
2		
3		
4		
5		
6		

iii. What are the two (2) most likely causes in this gentleman? (2 marks)

1 _____

2 _____

iv. State the one (1) management step that is most likely to relieve his symptoms (1 mark)

_____

v. State three (3) pros and three (3) cons for performing this management step for this patient in the emergency department as compared to on the ward (6 marks)

	Pros (3 marks)	Cons (3 marks)
1		
2		
3		

An 80 year old lady presents after an episode of syncope. She is currently asymptomatic.

An ECG is taken and is shown on page 14 of the props booklet.

i. List the abnormalities shown on this ECG. (5 marks)

1 _____

2 _____

3 _____

4 _____

5 _____

ii. What is the most likely explanation for this patients' current episode of syncope? (2 marks)

_____

_____

iii. List five (5) possible causes for this current problem (5 marks)

1 _____

2 _____

3 _____

4 _____

5 _____

iv. State your disposition for this patient. (1 mark)

_____

_____

v. Justify your disposition for this patient. (3 marks)

_____

_____

_____

_____

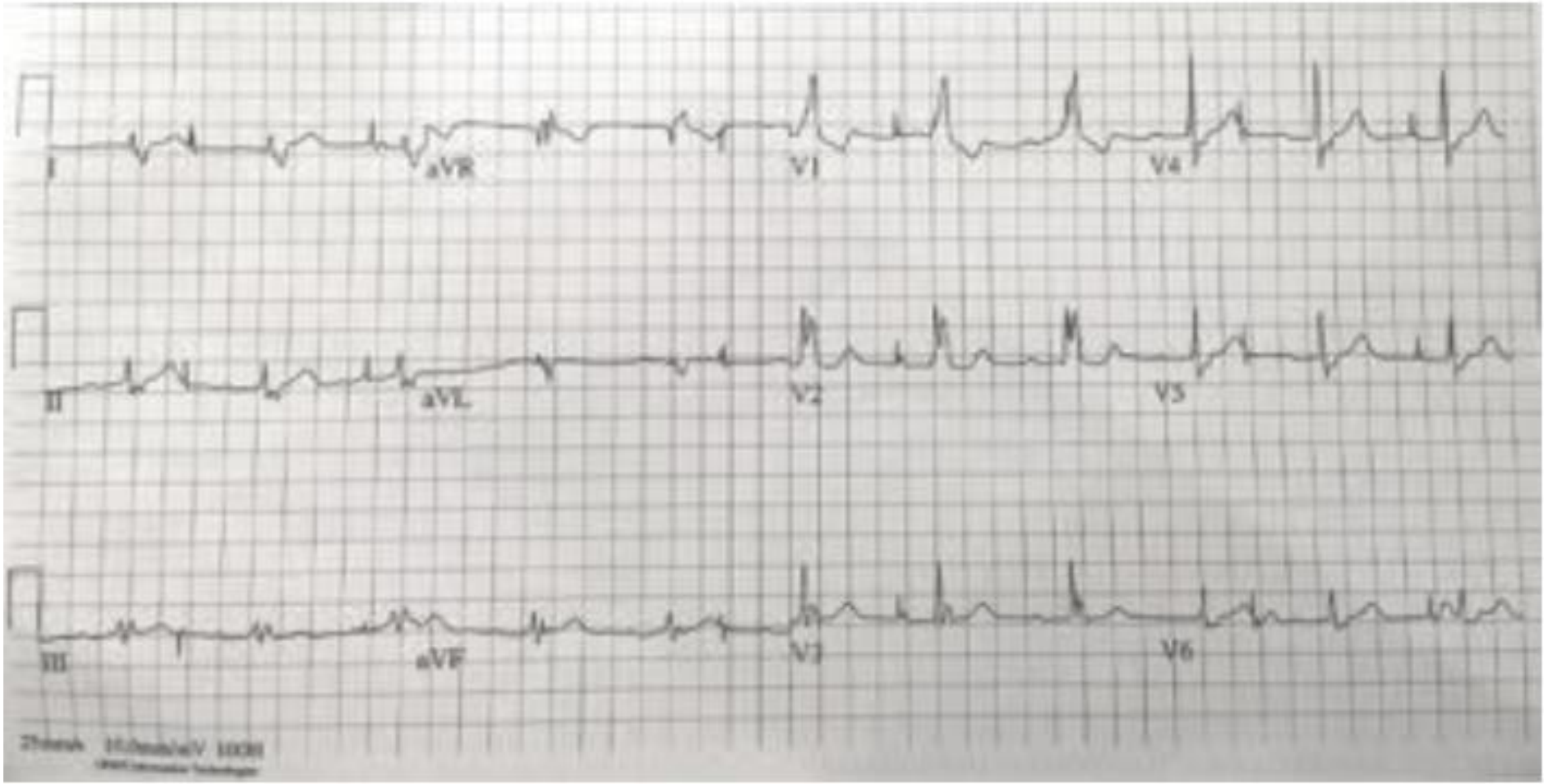
I
aVR
V1
V4
II
aVL
V2
V5
III
aVF
V3
V6

You are a consultant in a tertiary emergency department. A 31 year old man presents with 6 hours of severe central chest pain, on the background of a flu-like illness over the last week. Vital signs at presentation:

BP 100/60 mmHg RR 35/min

O2 Saturation 93% on room air Temperature 37.5°C

He is triaged to the resuscitation area. **An ECG is shown in props booklet ; page 2**

i) List three (3) abnormal findings in this ECG. (3 marks)

1. _____

2. _____

3. _____

Soon after this ECG is taken, his blood pressure falls to 85/50. His pulse is 110 (same rhythm pattern as shown in the ECG on page 1 of the props booklet). He is increasingly dyspnoeic.

ii) List five (5) likely differential diagnoses for his condition. (5 marks)

1. _____

2. _____

3. _____

4. _____

5. _____

iii) List five (5) key uses for bedside ultrasound in this patient. (5 marks)

1. _____

2. _____

3. _____

4. _____

5. _____

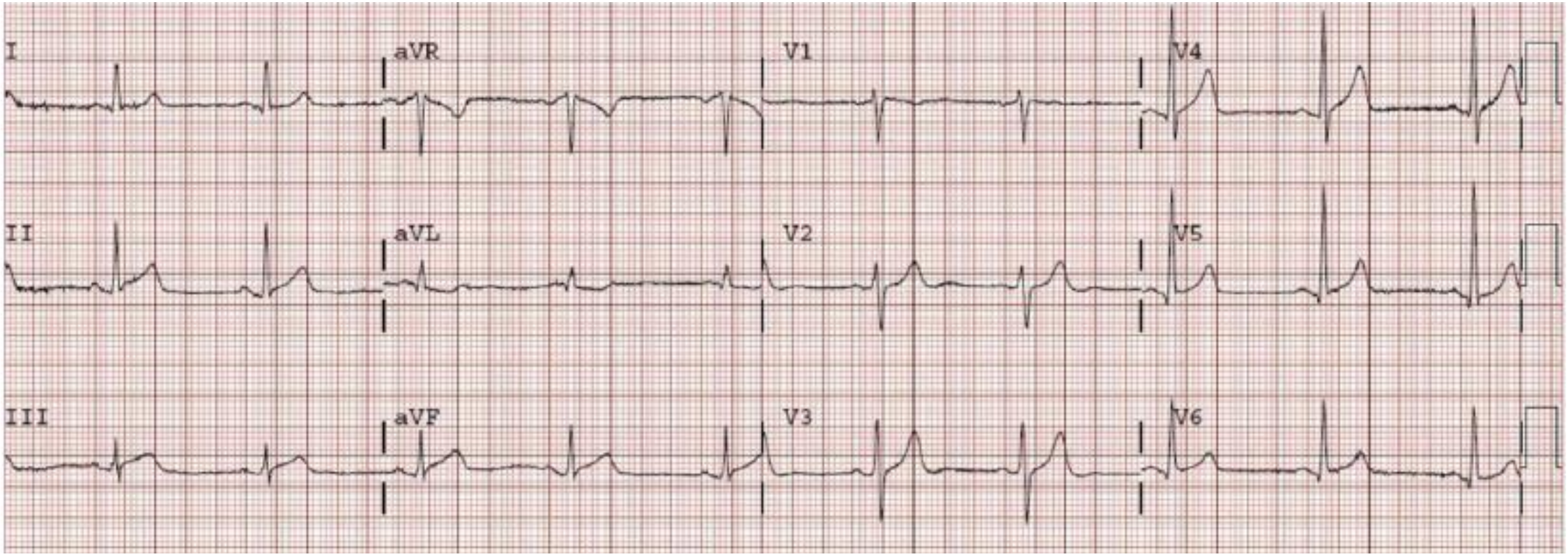
I
aVR
V1
V4
II
aVL
V2
V5
III
aVF
V3
V6

His haemodynamic state continues to deteriorate rapidly. Prior to any treatment, his blood pressure falls to 60/50 and his heart rate increases to 160 (same rhythm pattern as shown in the ECG on page 1 of the props booklet).

iv) List five (5) treatment options to improve his haemodynamics. List one (1) relevant detail for each of your choices . (10 marks)

	Treatment Option	Detail
1		
2		
3		
4		
5		

A 71 year old man presents with a 2 hour history of severe chest pain radiating through to his back. He has a past history of hypertension.

His observations:

BP	200/100	mmHg
PR	85	/min
RR	16	/min
Temp	36.5	°C
GCS	15	

A CT Aorta is shown in the PROPS booklet ; page 9.

i) List five (5) abnormal findings shown in this CT. (5 marks)

1. _____

2. _____

3. _____

4. _____

5. _____

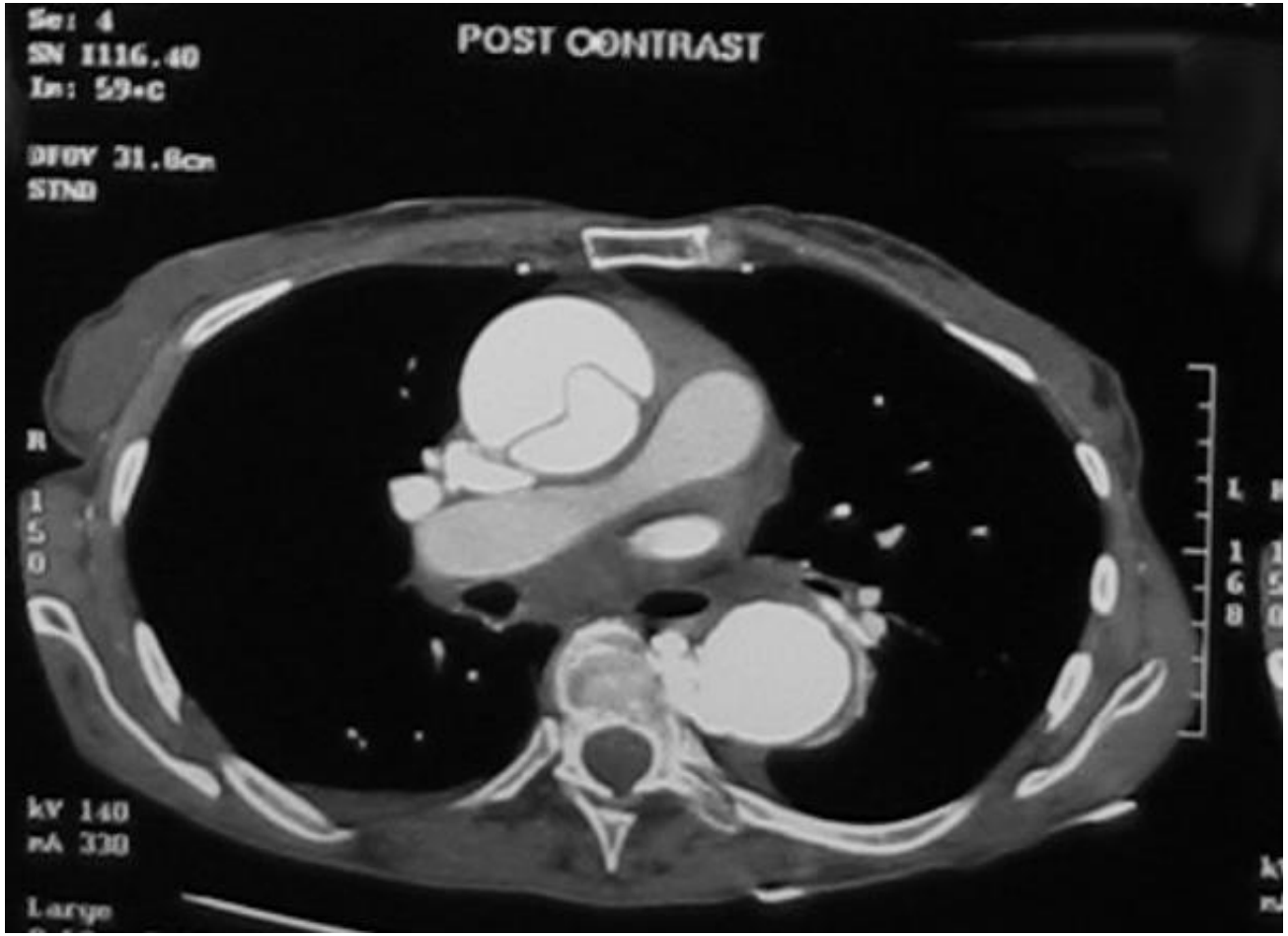

ii) List three (3) medications that you may use in the treatment of this condition. Provide one (1) justification for each choice. (6 marks)

	Medication (3 marks)	Justification (3 marks)
1.		
2.		
3.		

iii) State your choice of optimal definitive treatment for this patient. (1 mark)

_____

iv) List two (2) justifications for your choice of definitive treatment. (2 marks)

1. _____

2. _____

v) List five (5) factors that may lead you to not choose this optimal definitive treatment. (5 marks)

1. _____

2. _____

3. _____

4. _____

5. _____

A 48 year old man is brought to the Emergency Department with dyspnoea and a feeling of chest pressure. **His ECG is shown in PROPS booklet ;page 13.**

1) What is the diagnosis? (1 mark)

_____

_____

2) Justify your diagnosis by listing 3 positive findings on the ECG. (3 marks)

1. _____

_____

2. _____

_____

3. _____

_____

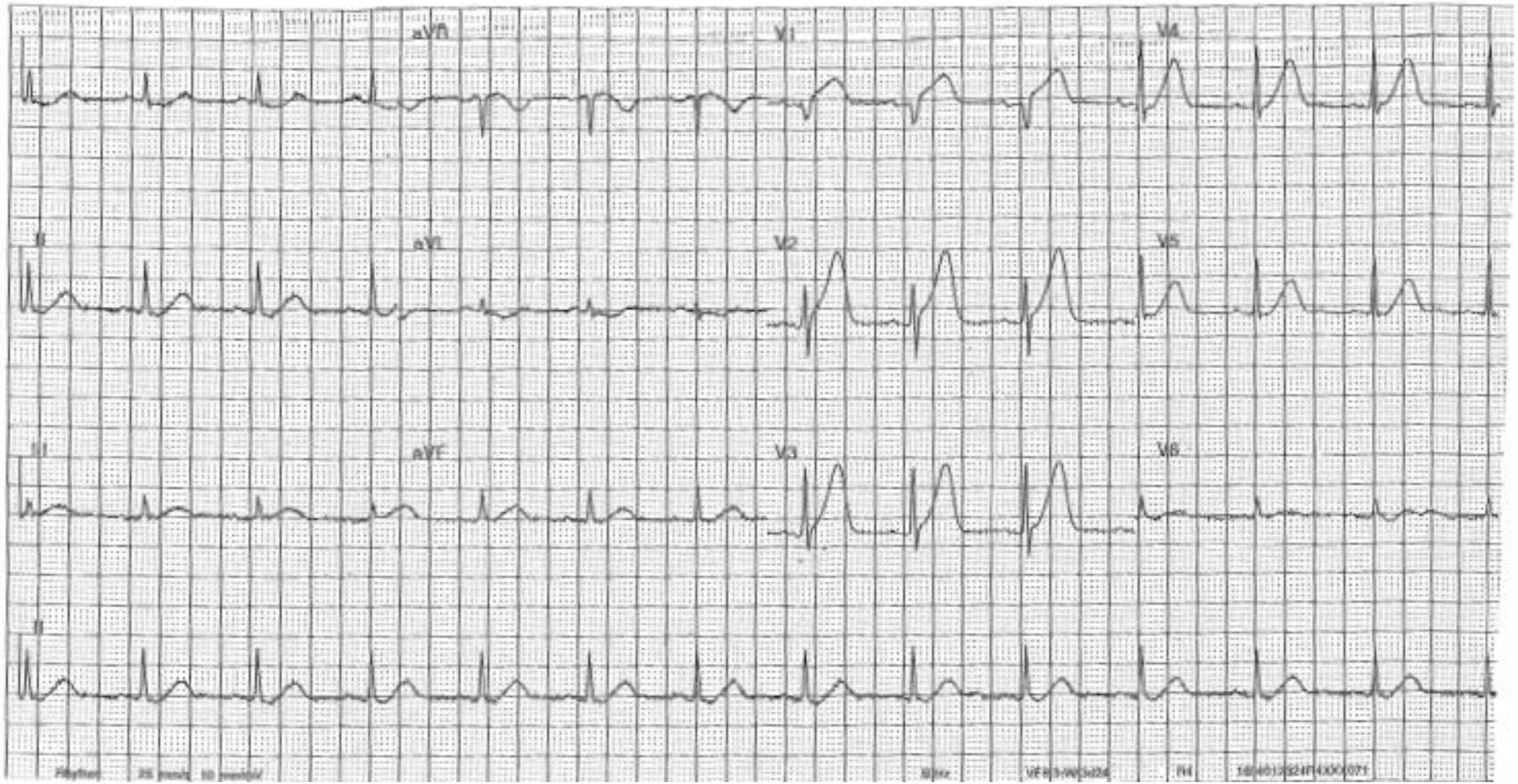
aVR
V1
V4
I
aVL
V2
V5
III
aVF
V3
V6
II

3) List two (2) differential diagnose and give one (1) justification why these are less likely than your provisional diagnosis. (4 marks)

	Differential	Justification
1		
2		

4) List five (5) points of history that you would seek to assist in the management of this patient (5 marks)

1. _____

2. _____

3. _____

4. _____

5. _____

5) List four (4) examination findings that are relevant to this presentation that would have a bearing on the patient's management (8 marks)

	Examination finding (4 marks)	**Affect on management (4 marks)**
1		
2		
3		
4		

A 70 years old man has been brought to the ED with marked dyspnea.

An ECG has been recorded and shown in PROPS booklet ; page 4 .

a) State four (4) abnormalities of his ECG. (4 marks)

1. _____

2. _____

3. _____

4. _____

b) Provide a unifying diagnosis for these abnormalities stating two (2) points in your answer? (2 marks)

_____

_____

c) List three (3) medications that you would consider for this patient. (3 marks)

1. _____

2. _____

3. _____

d) List two (2) procedures that may improve his dyspnoea.(2 marks)

1. _____

2. _____

e) The patient is found to be on warfarin and has an elevated INR. State four (4) factors that would help you determine if his warfarin activity should be reversed. (4 marks)

1. _____

2. _____

3. _____

4. _____

f) Patient experiences a VF arrest. What modification to standard defibrillation will be required? (1 mark)

_____

_____

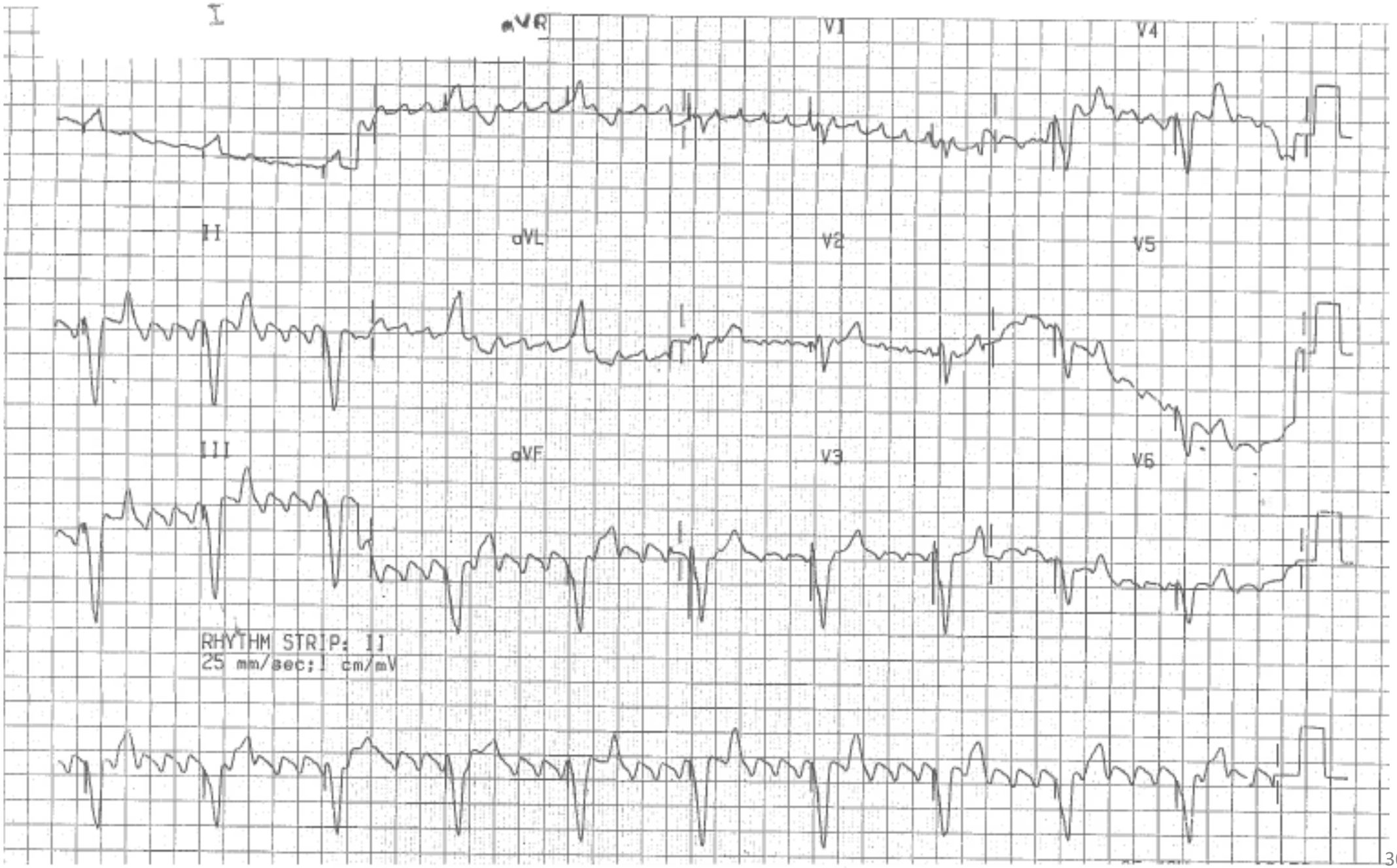
I
aVR
V1
V4
II
aVL
V2
V5
III
aVF
V3
V6
RHYTHM STRIP: II
25 mm/sec; 1 cm/mV

A 40 year old male has presented to the Emergency Department complaining of ongoing chest pain over the previous hour.

He has a past history of hypercholesterolemia and is taking no medications.

His 12 lead ECG is shown in PROPS BOOKLET ; Page 9.

a) List three (3) important findings on this man's ECG. (3 marks)

1. _____

2. _____

3. _____

b) What is the significance of the abnormalities in his ECG ? (1 mark)

_____

The junior cardiology registrar is uncertain what steps should be taken next and asks your advice.

c) What two important pieces of information would you give him? (2 marks).

1. _____

_____

2. _____

d) List your four (4) most urgent drug treatments; giving your rationale for each. (12 marks)

	Medication	Dosage - Route	RATIONALE
1			
2			
3			
4			

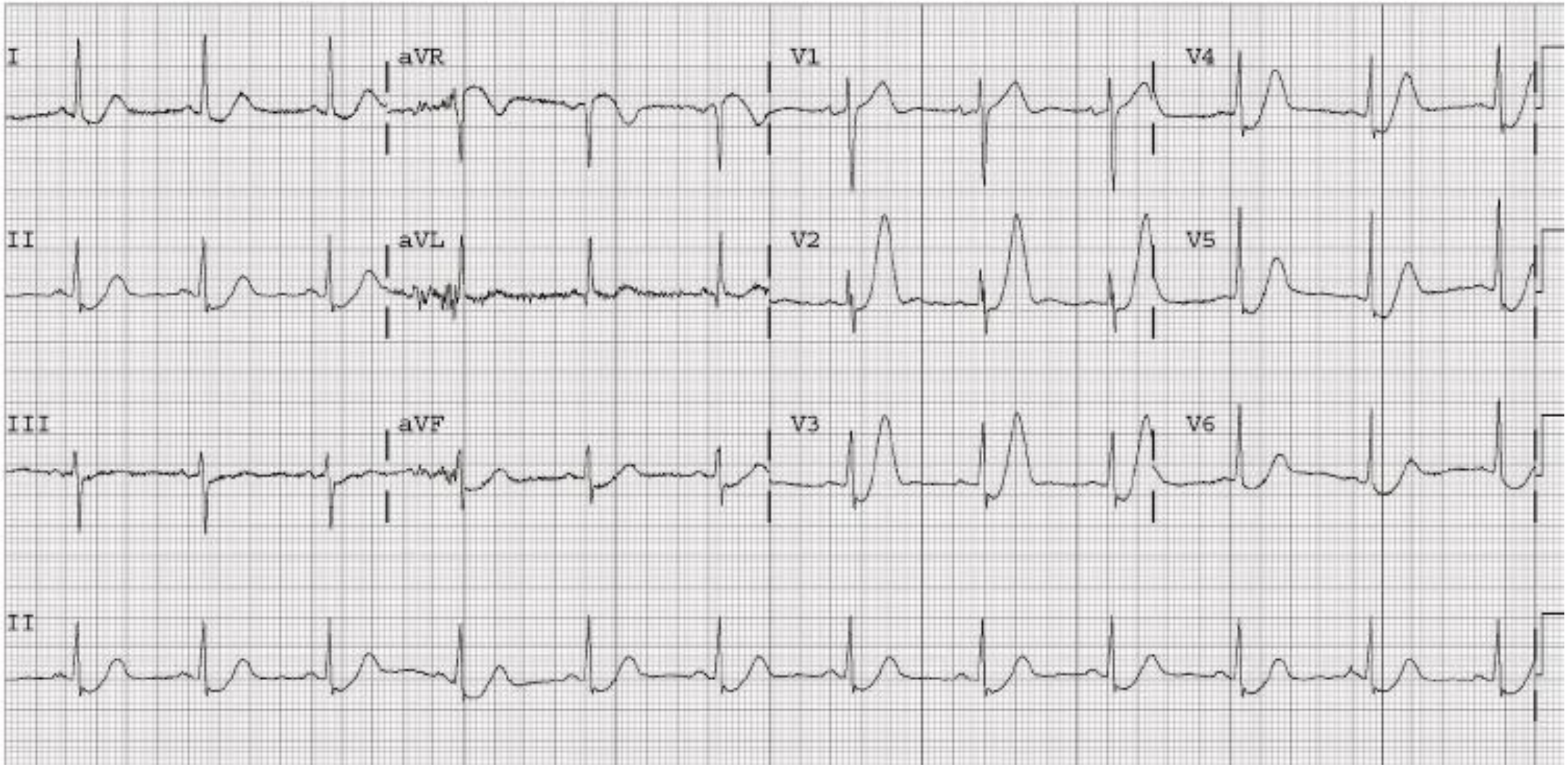
I
aVR
V1
V4
II
aVL
V2
V5
III
aVF
V3
V6
II

A 26 year old male, with no English from Vietnam has been brought to the Emergency Department following a syncopal episode.Your registrar says that blood tests including urea and electrolytes and troponin are normal and that the patient is well.
He attributes the episode to a "Vasovagal" and would now like to discharge the patient.
He tells you that the patient has a right bundle branch block, that he is not concerned about, but would like you to "sign off" on the patient's ECG as it is "Department Policy" for a Consultant to do this "in hours".

The patient's ECG is shown in PROPS BOOKLET ; Page 11 .

a) State two (2) educational points to the registrar relating to the ECG. (2 marks)

1. _____

_____

2. _____

_____

You enlist the assistance of a Vietnamese Interpreter.
b) List two (2) important questions you would like to ask this patient.(2 marks)

1. _____

_____

2. _____

_____

The patient suddenly feels faint but remains alert - whist an ECG is being done, the registrar asks for procainamide to be on hand, as he has read recently that this may be more effective than amiodarone in the setting of VT .

c) Give three (3) educational responses to this suggestion. (3 marks)

1. _____

_____

2. _____

_____

3. _____

_____

The symptoms resolve and the patient feels well. An ECG trace was not able to be procured documenting the event.
The patient, through the interpreter, says he now feels well and wishes to discharge himself.

d) State three (3) points would you make to the patient (3 marks)

1. _____

2. _____

3. _____

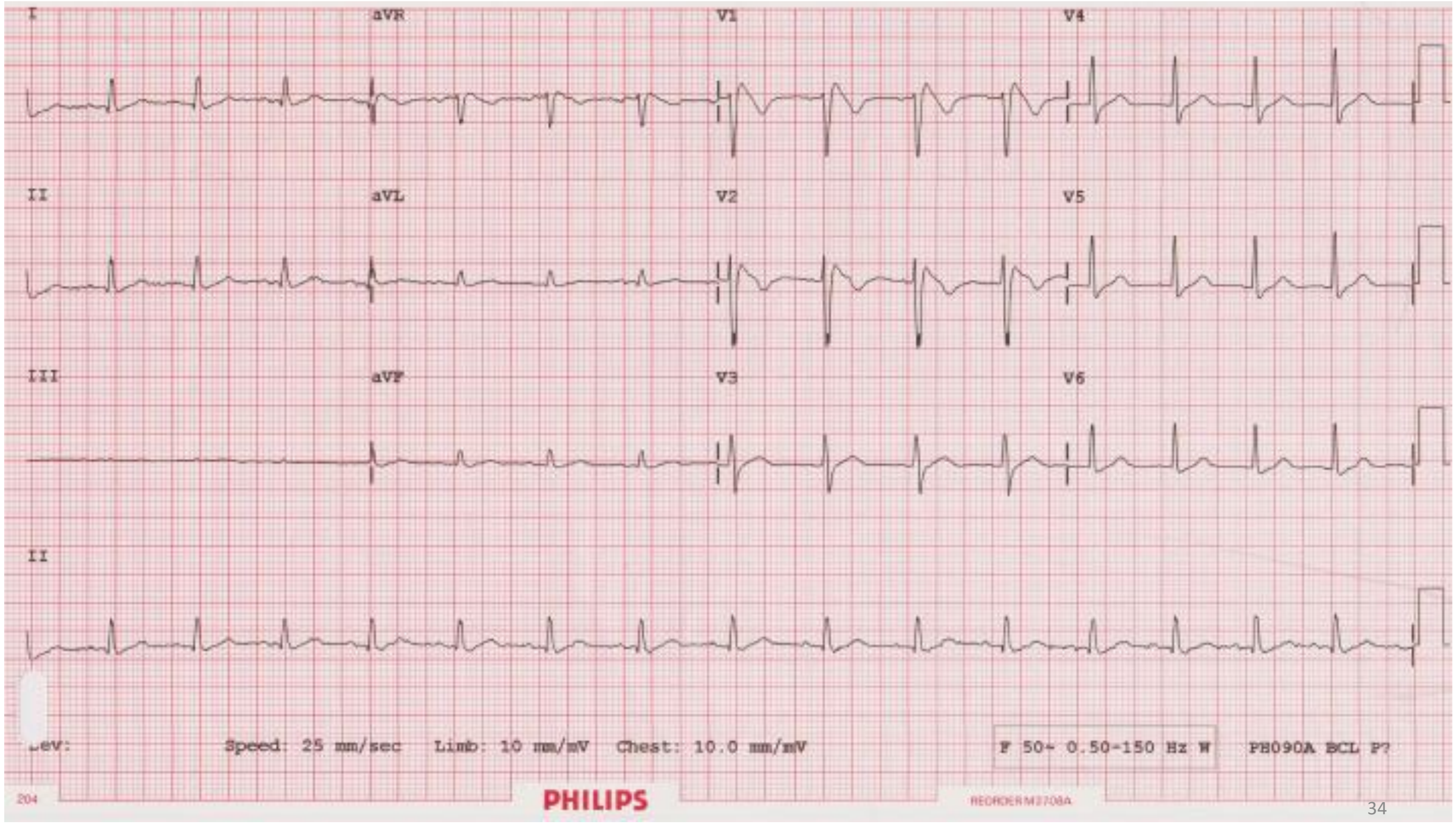
I
aVR
V1
V4
II
aVL
V2
V5
III
aVF
V3
V6
II
Speed: 25 mm/sec
Limb: 10 mm/mV
Chest: 10.0 mm/mV
F 50~ 0.50-150 Hz W
PH090A BCL P?
204
PHILIPS
REORDER M3708A

A 26 year old man presents with a 3 day history of sharp central chest pain suggestive of pericarditis. His observations are stable apart from a temp of 38C.

THE ECG IS SHOWN IN THE PROPS BOOKLET, PAGE 4

i. List the ECG abnormalities (3 marks)

ii. What ECG features would make a diagnosis of benign early repolarisation more likely? (2 marks)

iii. List 5 causes of pericarditis (5 marks)

iv. List 3 investigations used to detect a pericardial effusion in this setting – include a brief description of the positive finding for each investigation (6 marks)

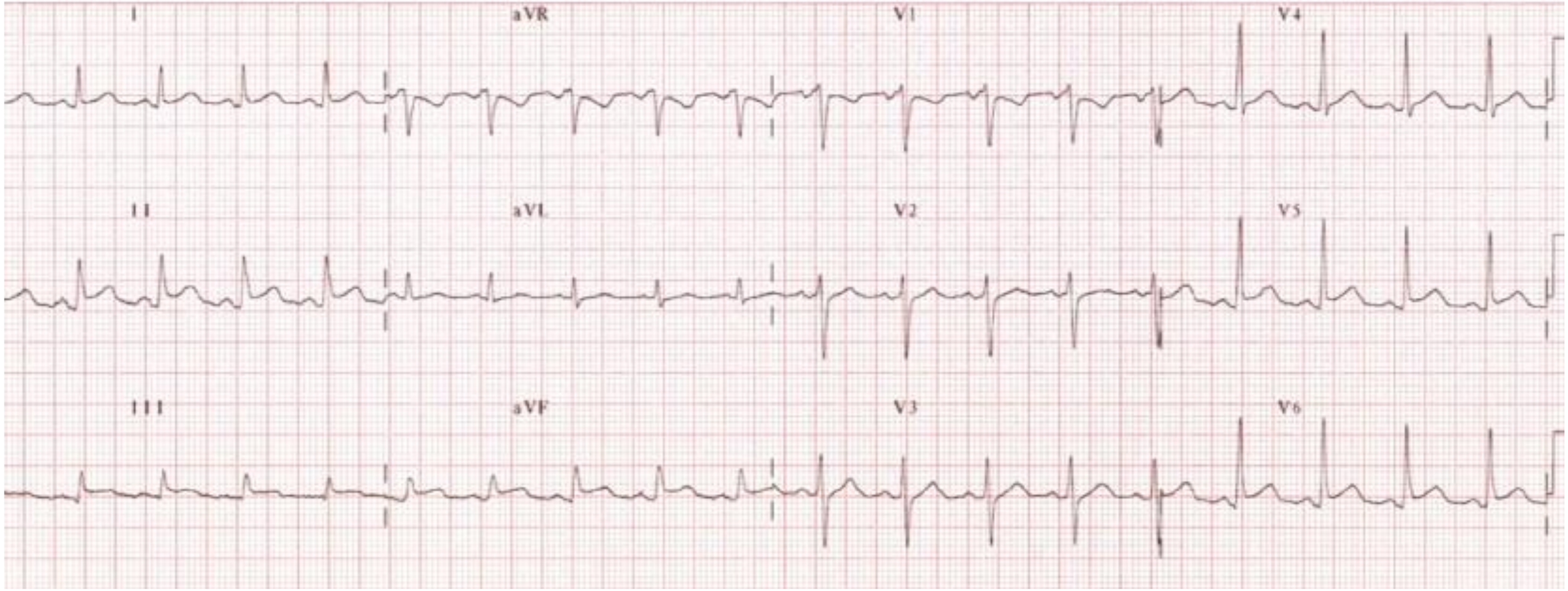
I
aVR
V1
V4
II
aVL
V2
V5
III
aVF
V3
V6

An 80yr female presents via ambulance from her GP to your ED. She has a 24 hour history of vomiting, followed by syncope this morning. She had a second syncope at her GPs office and was noted to be bradycardic on ambulance arrival.

Observations on arrival to ED are:

GCS 15

HR 76

BP 85/30

RR 18

SaO2 96% RA

She describes no chest pain, has had a recent course of antibiotics for a chest infection and has started on a "new drug for my memory".

THE PATIENT'S AMBULANCE RHYTHM STRIP AND ARRIVAL ECG ARE SHOWN IN THE PROPS BOOKLET, PAGE 9 & 10

i. List 3 relevant findings from the 12 lead ECG (3 marks)

ii. List 3 causes of the ECG abnormalities in this patient (3 marks)

iii. List your management priorities (4 marks)

She becomes bradycardic to 35 again, and her BP drops to 75/30 with a rhythm matching the initial ambulance ECG strip.

iv. What is her likely diagnosis? (1 mark)

v. You decide to initiate transcutaneous pacing for her transfer to ICU. Outline your approach (5 marks)



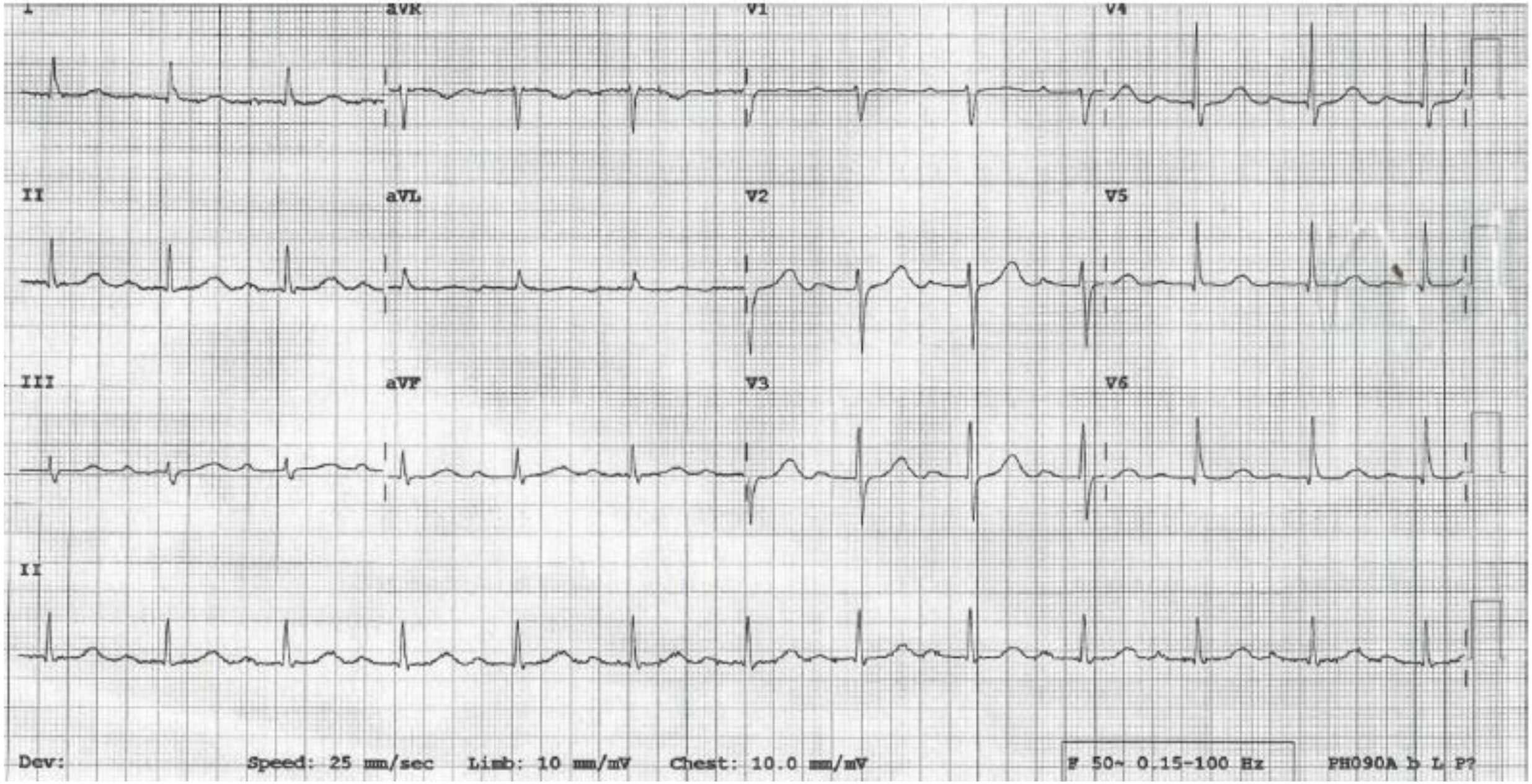
I
aVR
V1
V4
II
aVL
V2
V5
III
aVF
V3
V6
II
Dev:
Speed: 25 mm/sec
Limb: 10 mm/mV
Chest: 10.0 mm/mV
F 50~ 0.15-100 Hz
PH090A b L P?

A 70 year old man presents with ischaemic-sounding chest pain on a background of longstanding, poorly controlled hypertension. His 12-hour troponin is normal.

THE PATIENT'S ECG IS SHOWN IN THE PROPS BOOKLET, PAGE 11

i. List 4 abnormalities in this ECG (4 marks)

ii. List 5 causes of ST segment elevation other than myocardial ischaemia (5 marks)

iii. The patient is noted to have a systolic heart murmur. List 6 differential diagnoses of a systolic murmur (6 marks)

iv. You suspect this patient has aortic stenosis. What are the physical signs that suggest severe aortic stenosis? (4 marks)

v. Your registrar wants to commence a nitrate infusion for this man's angina. Outline your concerns about this plan (2 marks)

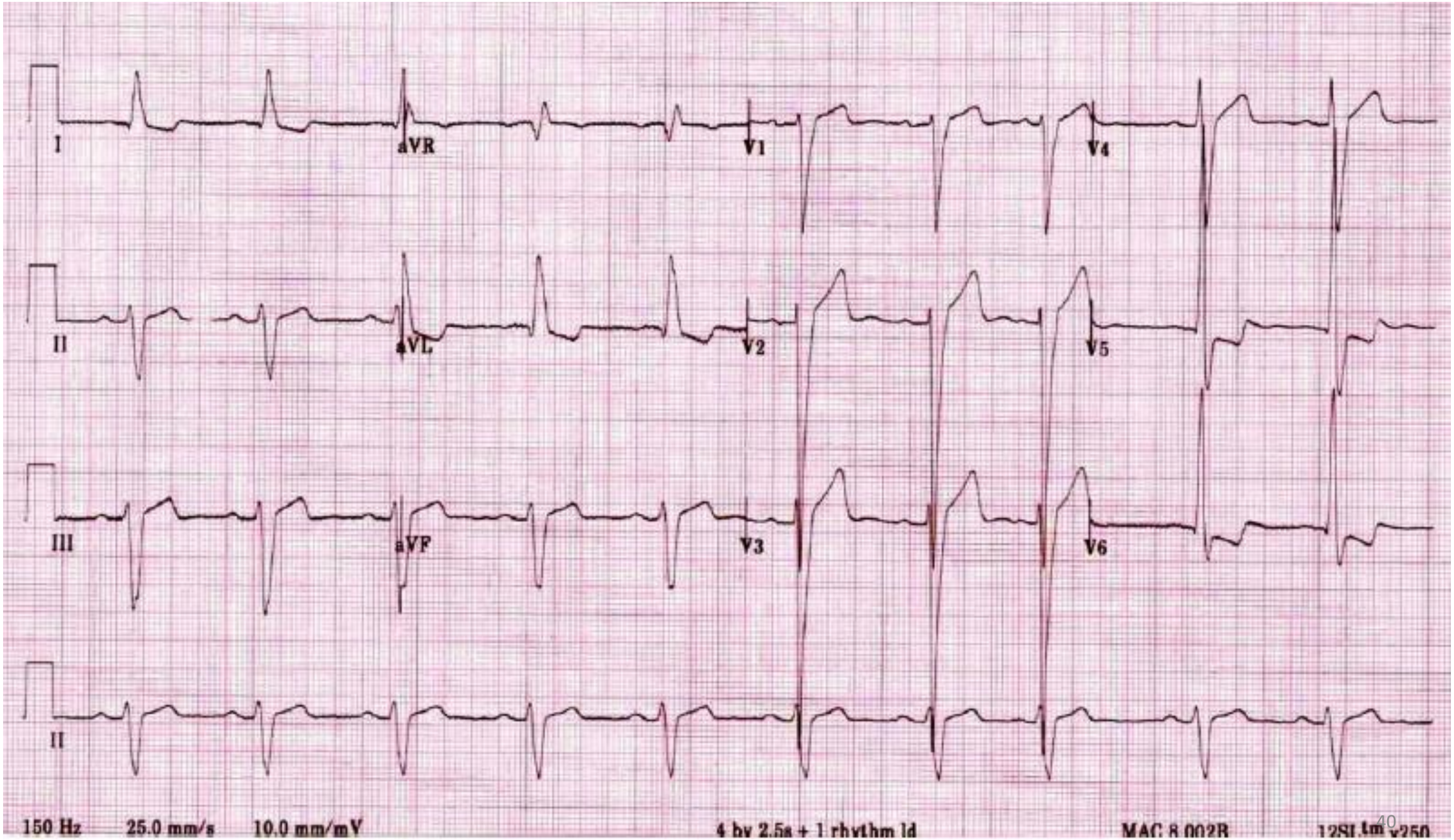
I
aVR
V1
V4
II
aVL
V2
V5
III
aVF
V3
V6
II
150 Hz
25.0 mm/s
10.0 mm/mV
4 by 2.5s + 1 rhythm ld
MAC 8 002B

A 67 year old woman has presented having found her blood pressure to be 205/130 on her home BP machine.

i. Define hypertensive emergency (2 marks)

ii. An image of the patient's retina is shown. Name two abnormalities seen (2 marks)

A CLINICAL PHOTOGRAPH IS SHOWN IN THE PROPS BOOKLET, PAGE 14

iii. List and justify 3 blood tests you might order in this patient (6 marks)

Blood Test	Justification

iv. Acute lowering of BP in profoundly hypertensive patients is indicated in a number of specific settings. Complete the table including two medications for each condition listed (doses not required). Identify the therapeutic goal and the blood pressure target (12 marks)

Diagnosis	Preferred agents (2 marks each)	Goal/Target (2 marks each)
Aortic dissection		
Myocardial ischaemia		
Intracerebral haemorrhage		

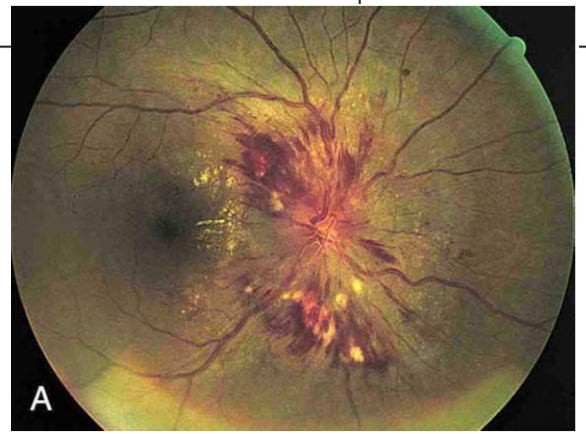

A 65 year old man presents to the emergency department with a history of palpitations.

His vital signs are:

BP	105/60	mmHg
RR	26	/min
Temperature	36.2	°C

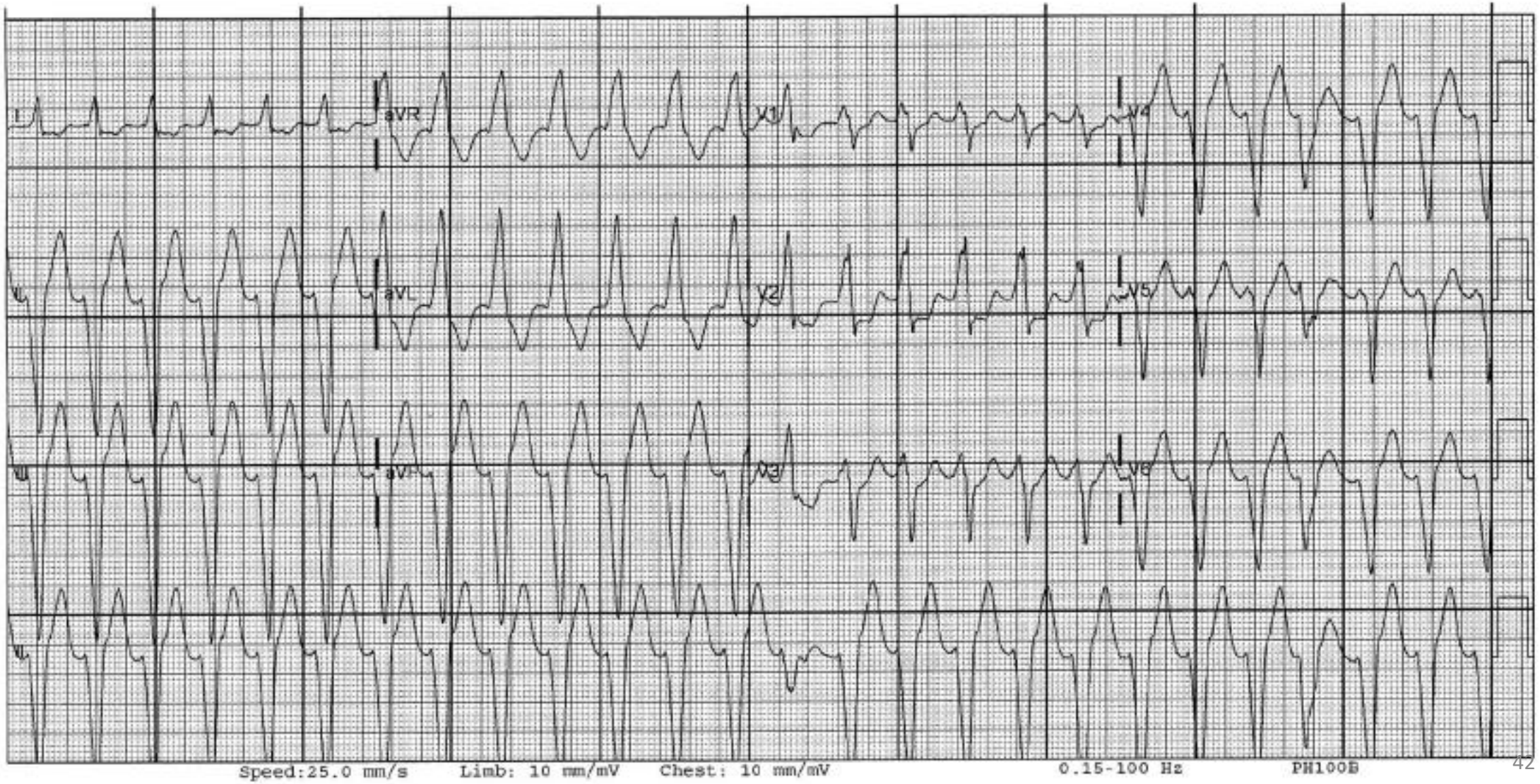

i. List four (4) of the ECG abnormalities you can see to support the diagnosis of Ventricular Tachycardia.

1. _____

2. _____

3. _____

4. _____

_____ /4

ii. List four (4) clinical features that would influence your decision to urgently electrically cardiovert this patient.

1. _____

2. _____

3. _____

4. _____

_____ / 4

iii. Assuming none of the features are present in (ii), list two (2) choices for chemical cardioversion, specifying drugs and doses.

	Drug	Dose
1		
2		

_____ / 4

A 71 year old woman presents to your emergency department following a collapse.

The attached ECG was taken on arrival in the emergency department.

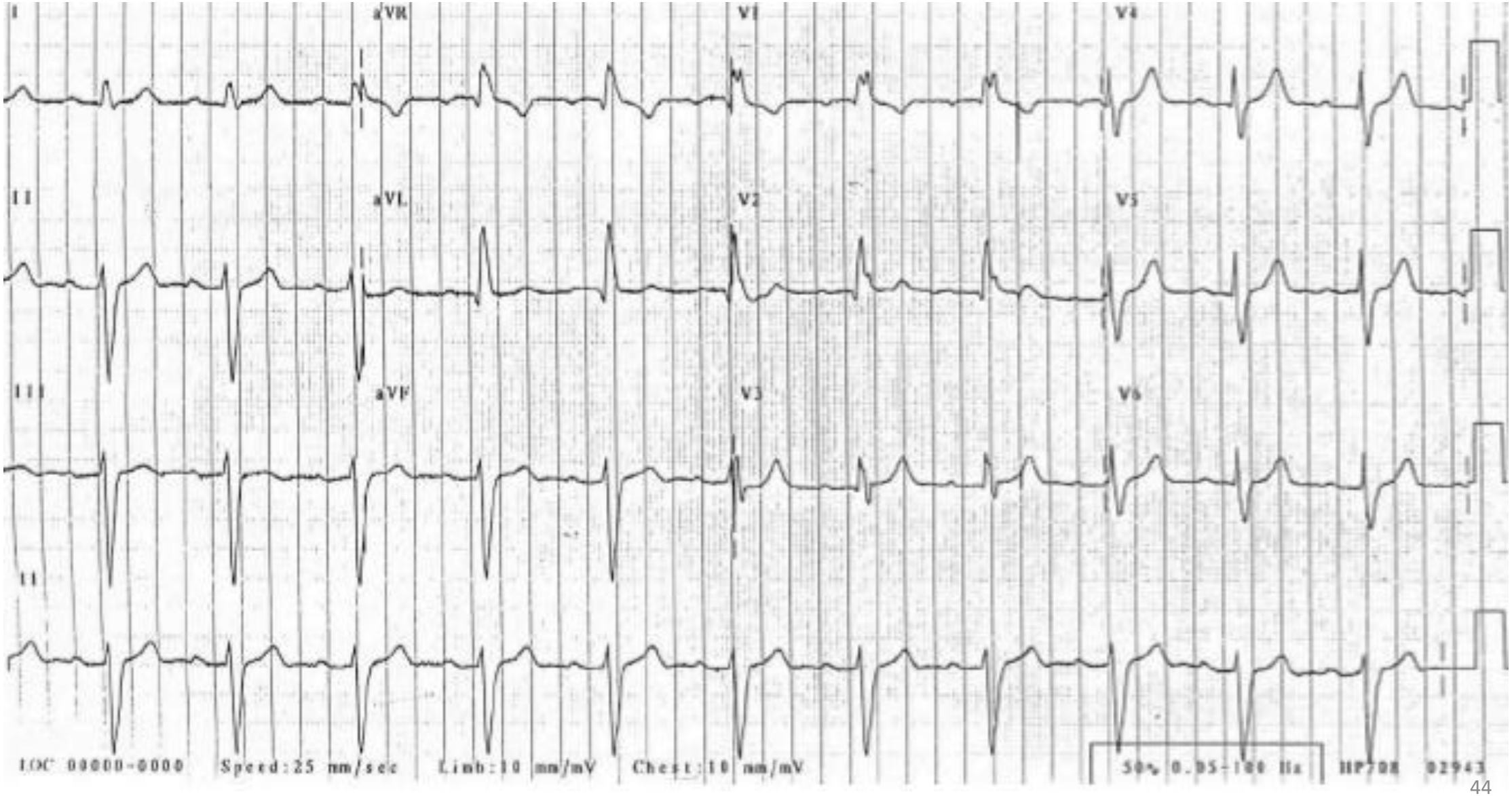

i. List three (3) features on history that are required for the diagnosis of syncope.

1. _____

2. _____

3. _____

_____ / 3

ii. List three (3) abnormalities on the ECG and a unifying diagnosis.

1. _____

2. _____

3. _____

Unifying diagnosis: _____

_____ / 4

iii. Give one (1) potential complication of the ECG changes.

_____

iv. Provide four (4) relevant management decisions based on your answer to questions (ii) and (iii).

1. _____

2. _____

3. _____

4. _____

_____ / 4

A 72 year old female is brought to your Emergency Department following a syncopal episode.
Vital signs:

BP 152 / 86
RR 19
Sats 98% RA

Temp 35.9 °C
BSL 7.2 mmol/L

a. Describe and interpret the key features on her ECG (5 Marks)

b. Outline your disposition considerations (5 Marks)

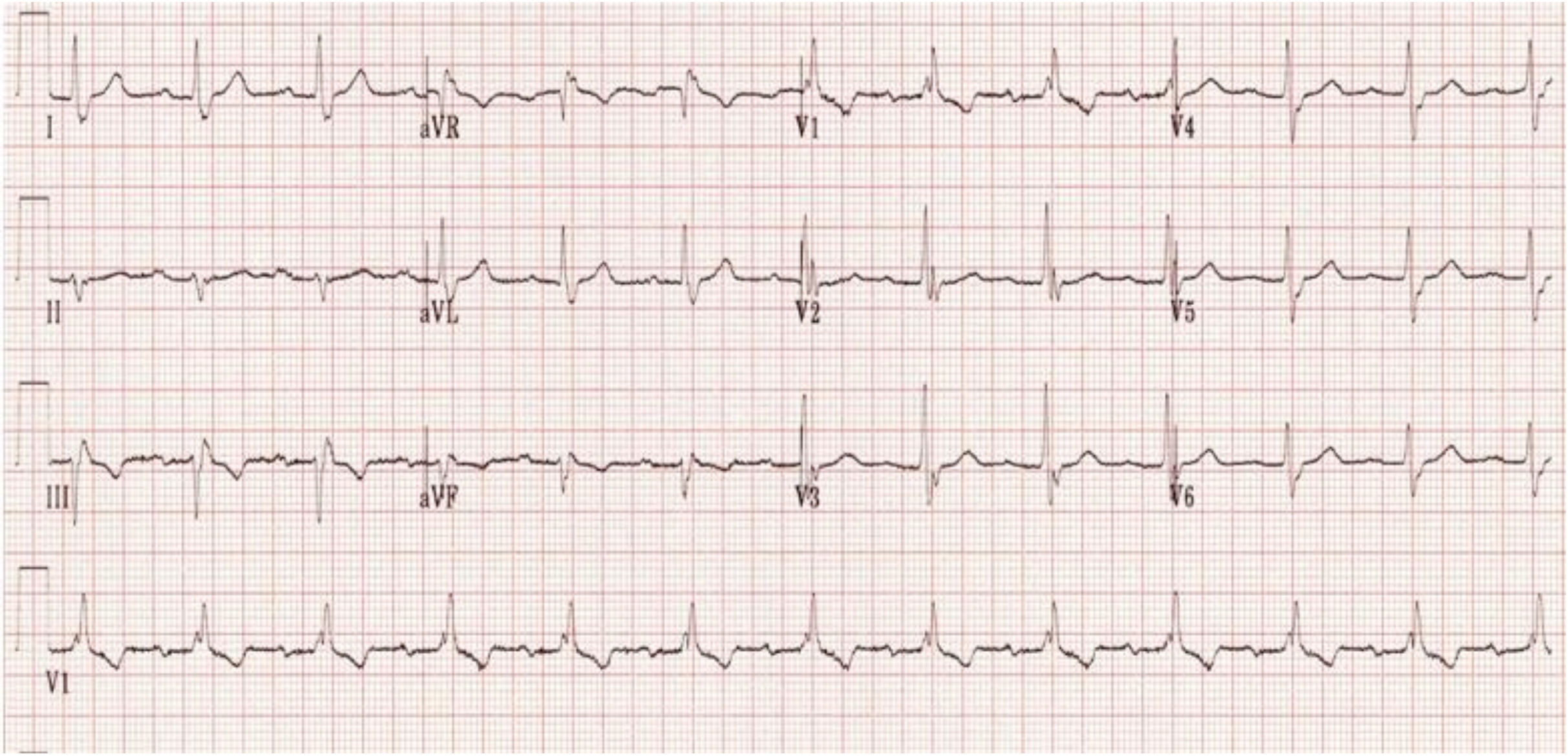
I
aVR
V1
V4
II
aVL
V2
V5
III
aVF
V3
V6
VI

A 68-year old woman presents by ambulance to your Emergency Department. She complains of chest pain and general lethargy. She has a history of hypertension, atrial tachyarrhythmia and has a PPM in situ.

Vital signs:

BP 98/65
RR 20
Sats 100% on 2 L/min

Temp 36.3 °C
BSL 6.1 mmol/L

a. Describe the key features on her ECG (5 Marks)

b. List the potential causes for the ECG changes (5 Marks)

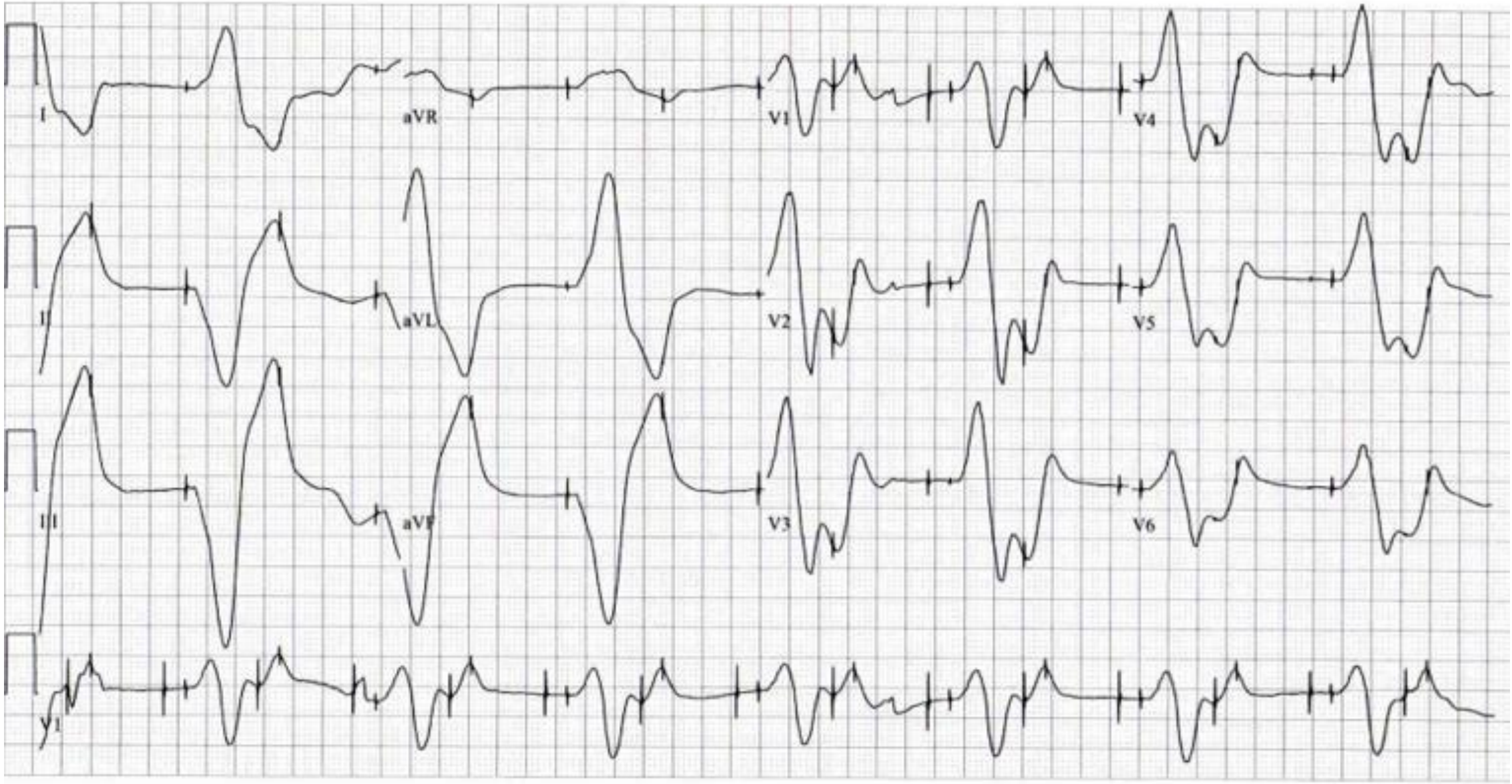
I
aVR
V1
V4
II
aVL
V2
V5
III
aVF
V3
V6
y1

A 35 yr old male who presents to your Emergency Department complaining of palpitations, dysponea, and light-headedness for the preceding hour. He has no known past medical history.

Vital signs:

BP 115/65
RR 20

Sats 98% RA
Temp 36.6 ^{O}C

a. Describe and interpret his ECG (5 Marks)

b. Outline your management of this patient (5 Marks)

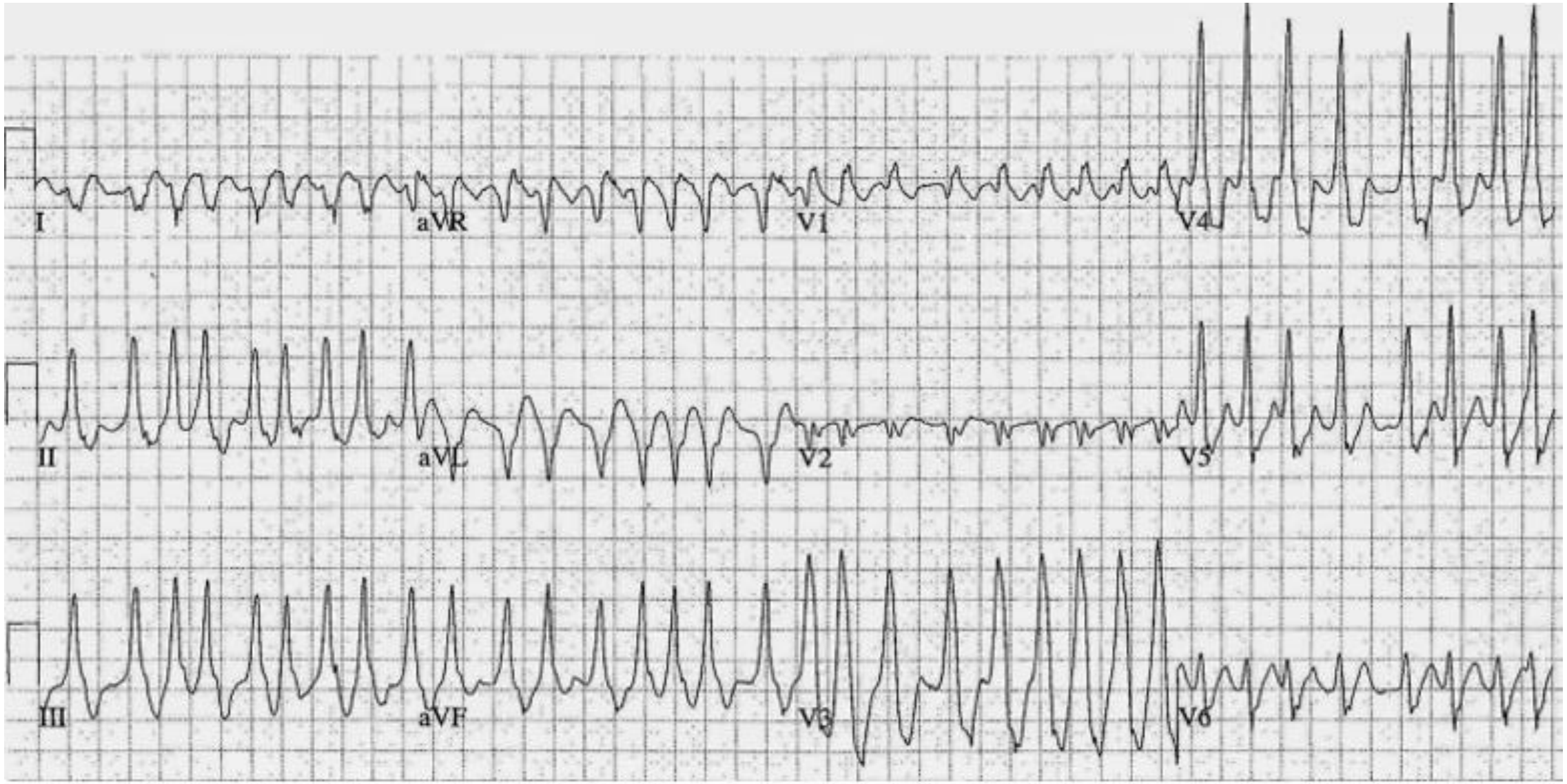
I
aVR
V1
V4
II
aVL
V2
V5
III
aVF
V3
V6

A 52 year old male presents to your Emergency Department with ischaemic sounding chest pain. He has not been seen in any hospital in the last 12 months and has never had Echocardiography.

a) State seven (7) factors that, in combination, would allow safe discharge within 3 hours from presentation. (7 marks)

1. _____

2. _____

3. _____

4. _____

5. _____

6. _____

7. _____

b) If the patient underwent an ECG that demonstrated a left bundle branch block, state three (3) ECG findings that may be useful for identifying myocardial infarction. (3 marks)

1. _____

2. _____

3. _____

An ECG is taken on arrival and shown on **PROPS BOOKLET ; PAGE 3.**

a) State three (3) significant abnormal findings in this ECG. (3 marks)

1. _____

2. _____

3. _____

b) State the significance of these abnormal findings. State two (2) points in your answer. (2 marks)

1. _____

2. _____

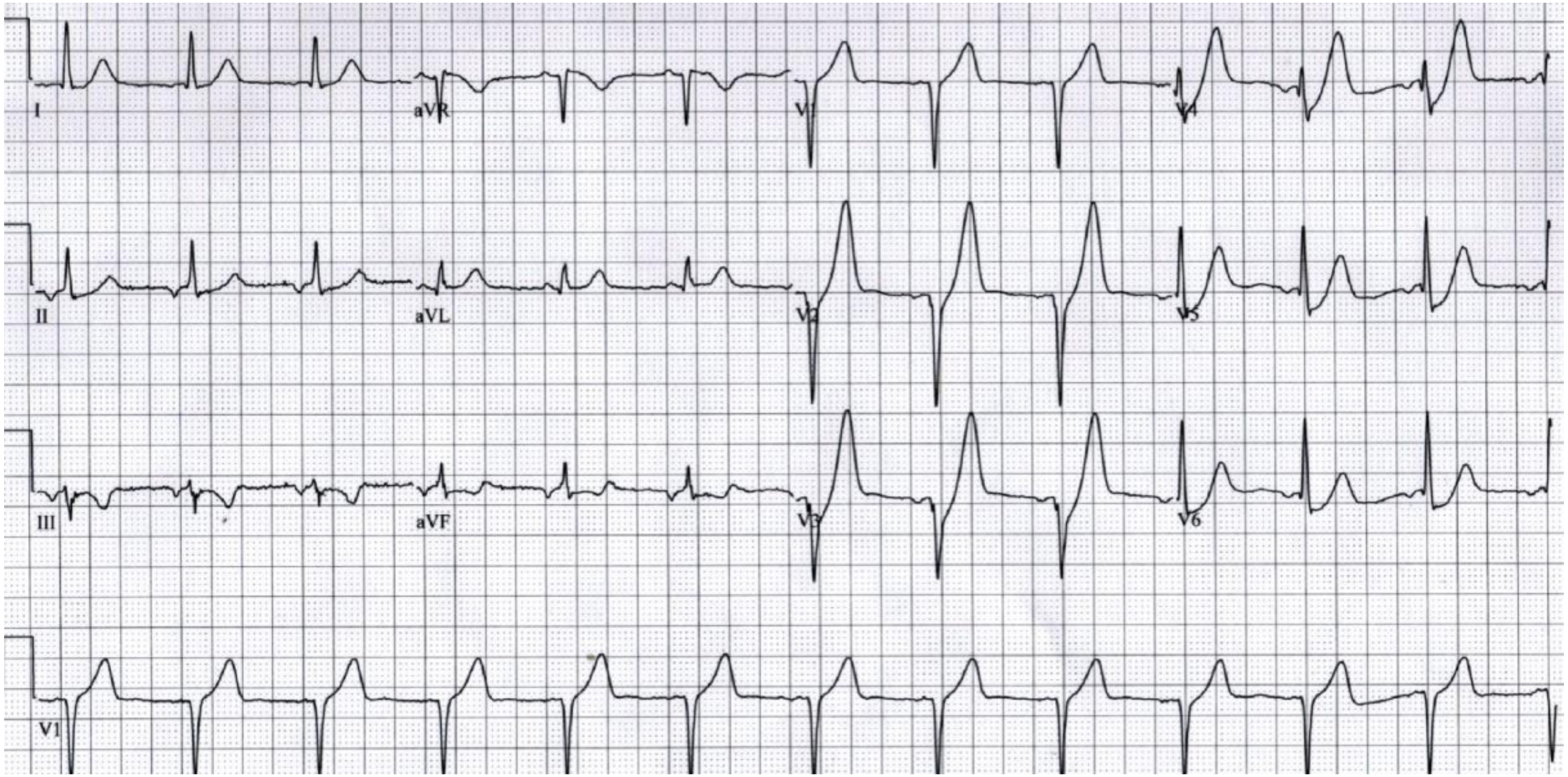
I
aVR
V1
V4
II
aVL
V2
V5
III
aVF
V3
V6
V1

Aspirin, GTN and morphine are provided for this patient.
The patient has ongoing ischaemic sounding chest pain.
His observations are:

BP	130/60	mmHg
HR	90	bpm
RR	14	bpm
Sats	94%	RA

c) List three (3) further medications that are indicated for this patient. (3 marks)

1. _____

2. _____

3. _____

A 17 year old male is brought your district ED by his nurse mother after feeling dizzy and unwell and appearing 'pale' on the football field. He was reluctant to attend as he felt 'fine'. Presenting blood pressure 115/60. Saturations 99% on room air. RR 14. Afebrile. Triage ECG performed.

i. Describe and interpret his ECG (5 marks) **SEE PROPS BOOKLET – IMAGE G**

ii. List up to 5 questions you would like to ask on history, regarding symptoms (5 marks)

iii. List and justify up to 3 initial investigations you would like to perform (3 marks)

iv. Prior to any further investigation, he tells you he wants to discharge against your advice. List your management priorities now (3 marks)

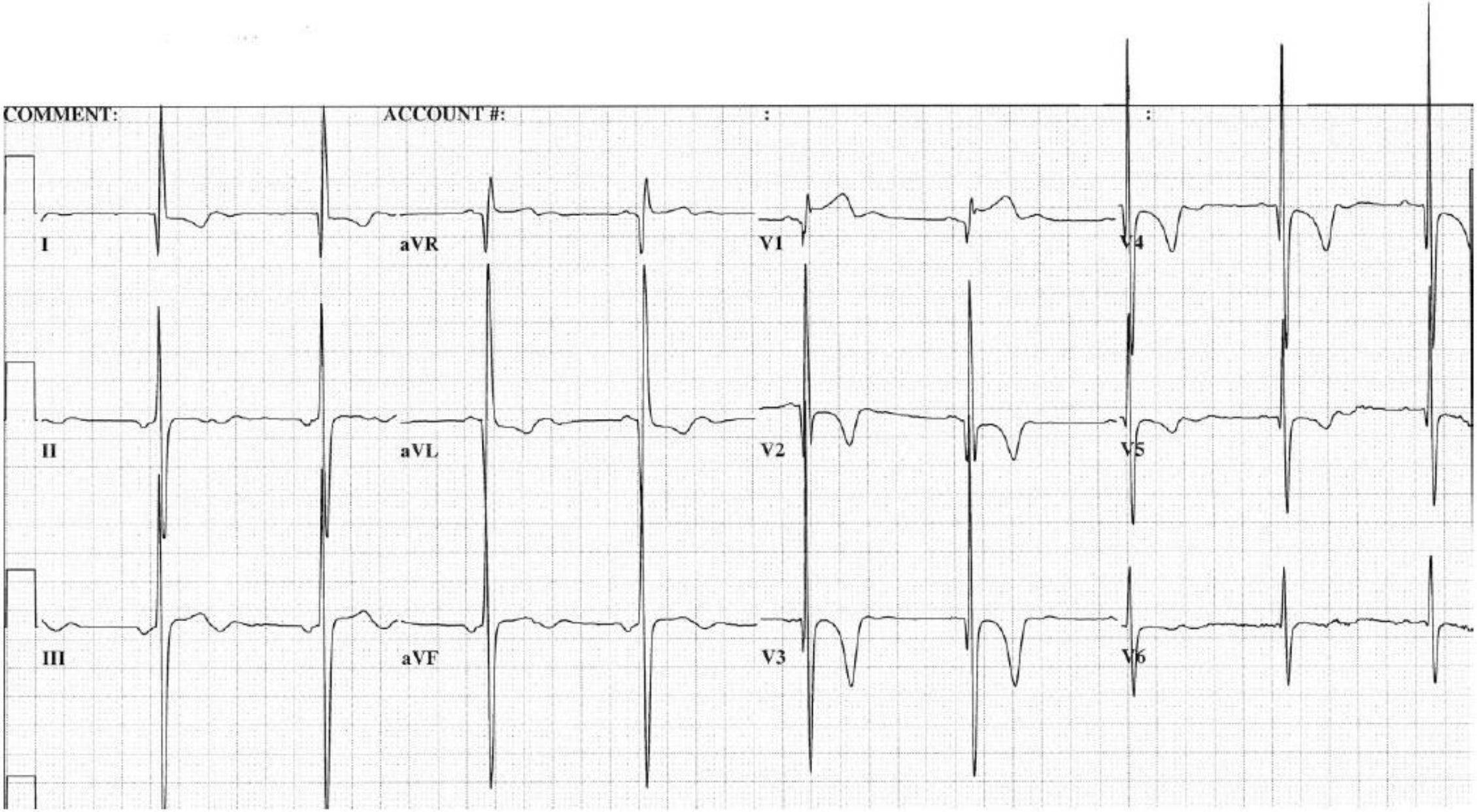
COMMENT:
ACCOUNT #:
:
:
I
aVR
V1
V4
II
aVL
V2
V5
III
aVF
V3
V6

A 16 year old girl presents to ED after syncope during a running event at the school sports carnival. Her vital signs are GCS 15, P 70, BP 118/70, RR 18 and afebrile.

i. List 6 relevant historical features (6 marks)

ii. List 3 relevant findings on the ECG, and your provisional diagnosis (4 marks)

AN ECG IS SHOWN IN THE PROPS BOOKLET, PAGE 11

iii. List your subsequent steps in management (3 marks)

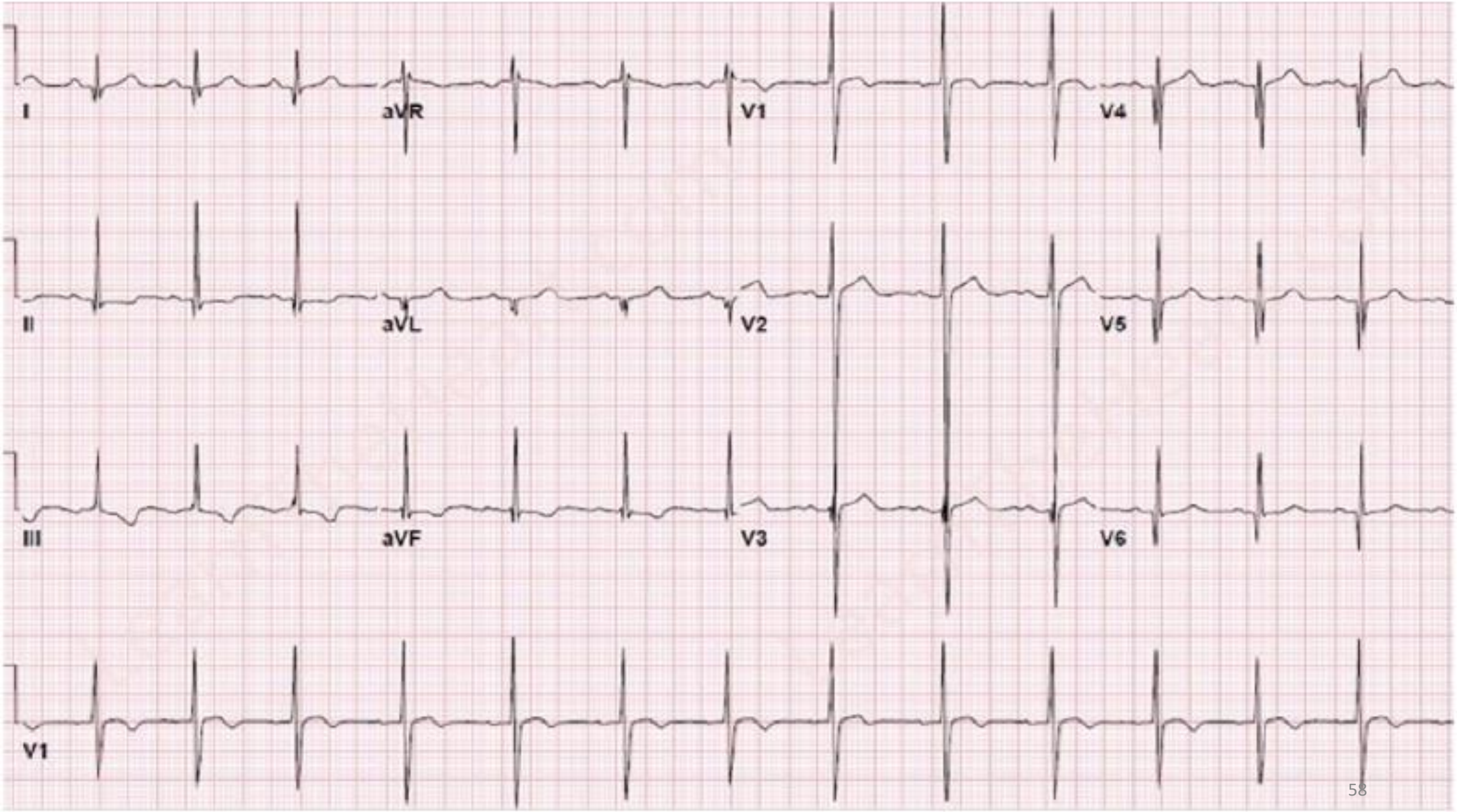
I
aVR
V1
V4
II
aVL
V2
V5
III
aVF
V3
V6
V1

A 52 year old male presents to your Emergency Department with ischaemic sounding chest pain. He has not been seen in any hospital in the last 12 months and has never had Echocardiography.

a) State seven (7) factors that, in combination, would allow safe discharge within 3 hours from presentation. (7 marks)

1. _____

2. _____

3. _____

4. _____

5. _____

6. _____

7. _____

b) If the patient underwent an ECG that demonstrated a left bundle branch block, state three (3) ECG findings that may be useful for identifying myocardial infarction. (3 marks)

1. _____

2. _____

3. _____

An ECG is taken on arrival and shown on **PROPS BOOKLET ; PAGE 3.**

a) State three (3) significant abnormal findings in this ECG. (3 marks)

1. _____

2. _____

3. _____

b) State the significance of these abnormal findings. State two (2) points in your answer. (2 marks)

1. _____

2. _____

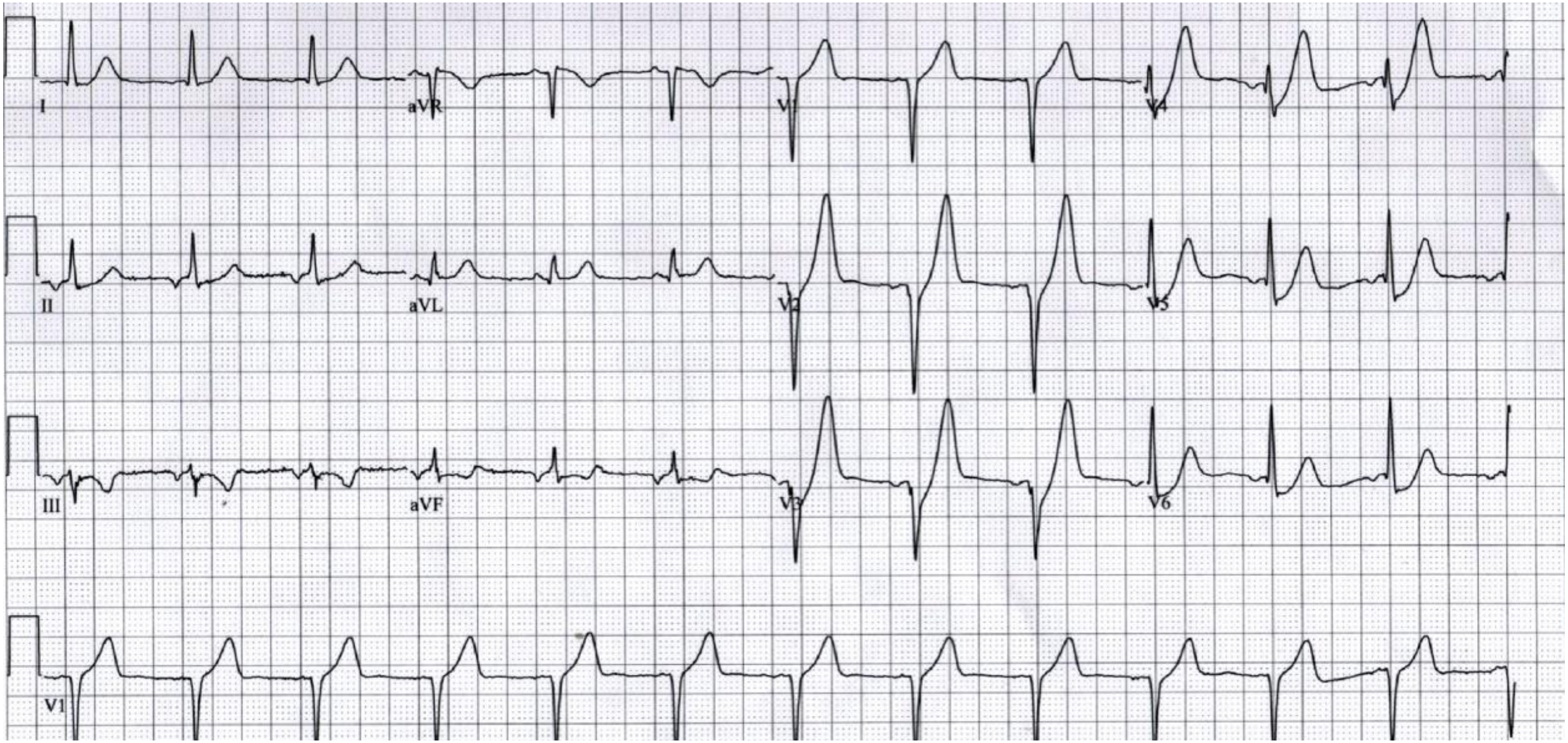
I
aVR
V1
V4
II
aVL
V2
V5
III
aVF
V3
V6
V1

Aspirin, GTN and morphine are provided for this patient.
The patient has ongoing ischaemic sounding chest pain.
His observations are:

BP	130/60	mmHg
HR	90	bpm
RR	14	bpm
Sats	94%	RA

c) List three (3) further medications that are indicated for this patient. (3 marks)

1. _____

2. _____

3. _____

A 65 year old male has presented to the Emergency Department complaining of chest pain.

As the triage nurse is performing an ECG, the patient loses consciousness.

His 12 lead ECG is shown in **PROPS BOOKLET; PAGE 10.**

a) List three (3) important findings on this ECG and the state the reason for the importance of each finding. (6 marks)

	ECG finding	Importance
1		
2		
3		

b) For each of the following methodologies for estimating the QT interval state its utility in this patient. (3 marks)

	Methodology	Utility
1		
2		
3		

Despite multiple defibrillations the patient continues to have recurrences of the above dysrrhythmia.

During the resuscitation a friend brings in the patients medications - which include Sotalol

c) List two (2) further interventions you would consider.(2 marks)

1. _____

2. _____

d) List one (1) drug agent that may need to be avoided. (1 mark)

_____

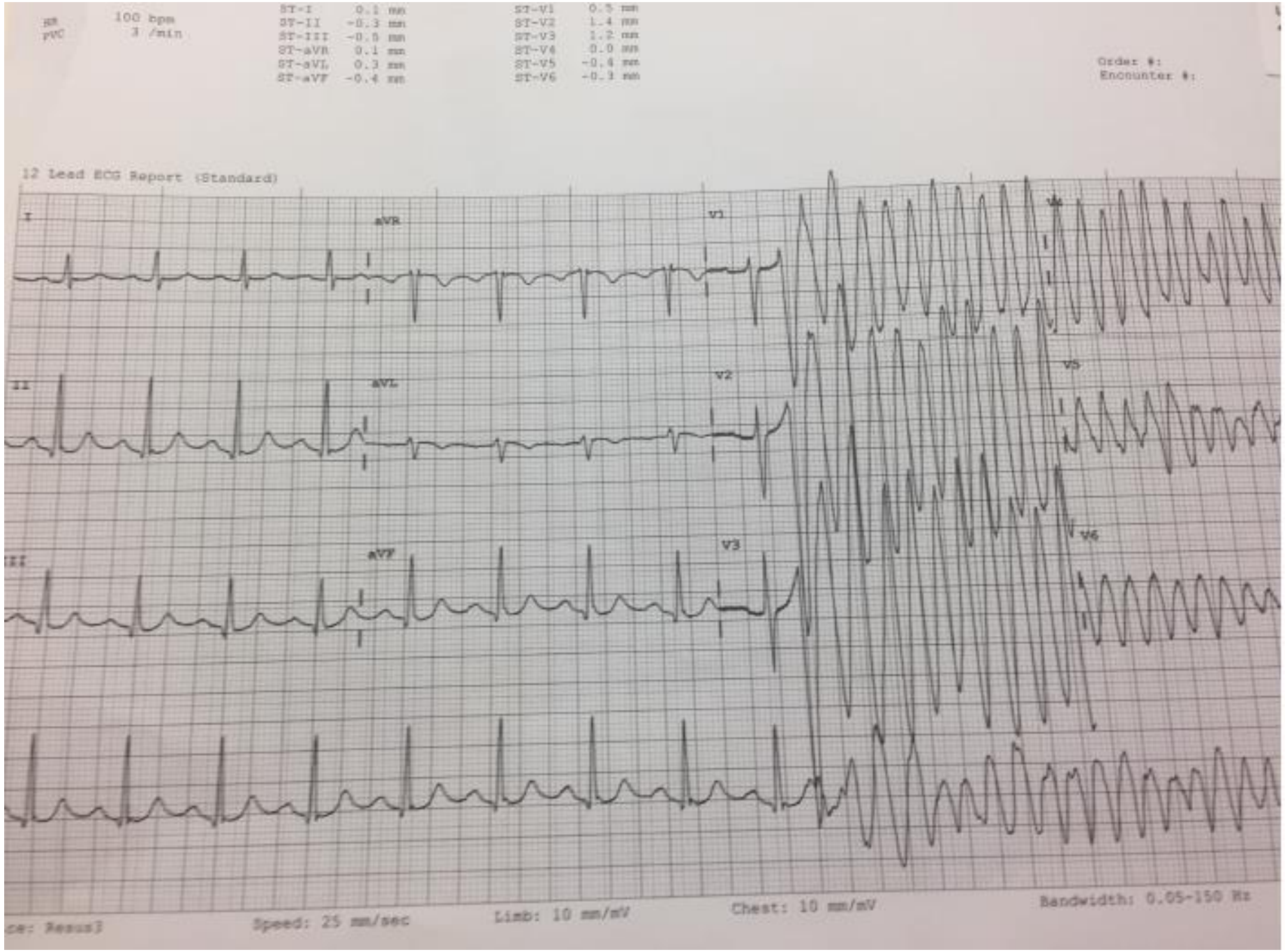
100 bpm
3 /min
ST-I 0.1 mm
ST-II -0.3 mm
ST-III -0.5 mm
ST-aVR 0.1 mm
ST-aVL 0.3 mm
ST-aVF -0.4 mm
ST-V1 0.5 mm
ST-V2 1.4 mm
ST-V3 1.2 mm
ST-V4 0.0 mm
ST-V5 -0.4 mm
ST-V6 -0.3 mm
Order #:
Encounter #:
12 Lead ECG Report (Standard)
I
aVR
V1
II
aVL
V2
V5
III
aVF
V3
V6
Speed: 25 mm/sec
Limb: 10 mm/mV
Chest: 10 mm/mV
Bandwidth: 0.05-150 Hz

A 38-year-old female presents with BP 220/125 and a headache.

1. Define Hypertensive emergency. (1 mark)

_____

_____

_____

2. List 6 end organs that might be damaged from severe hypertension and at least one clinical manifestation that you might find on history taking, examination and the appropriate investigation. Name the medication of choice for management of that. (6 marks)

Organ	Symptom or Sign	Investigation

3. List 2 classes of medication, 2 examples of that class and the dose that can be used for the treatment of hypertensive emergencies. (4 marks)

Class of Medication	Example	Dose & Frequency of Treatment

A 74-year-old woman presents with light-headedness, lethargy and palpitations.

Her vital signs are BP 100/60, HR 124/min, temp 37, SaO2 99% on room air.

She has a past medical history of type 2 diabetes, hypertension and has a pacemaker for heart block. Her pacemaker card indicates she has a DDD pacemaker.

1. Describe the DDD function of her pacemaker. (2 marks)

_____

_____

_____

_____

See ECG on page 23 in separate book

2. Describe her ECG. (2 marks)

_____

_____

_____

3. List 2 differential diagnoses (2 marks)

(1) _____

(2) _____

4. List 4 management steps you would initiate for her. (4 marks)

(1) _____

(2) _____

(3) _____

(4) _____

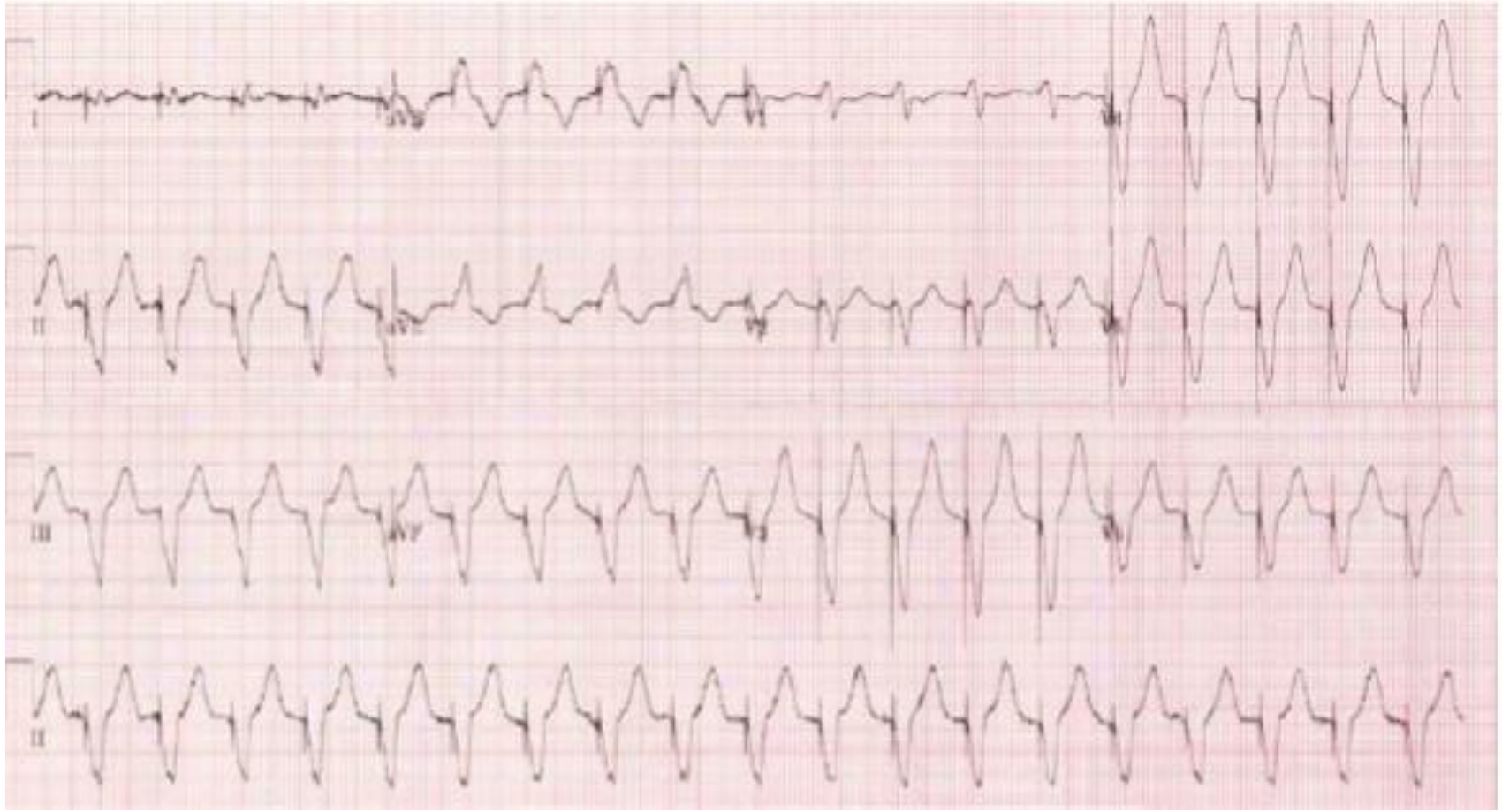
I
II
III
II

A 78 year old female presents with a 24 hour history of exercise induced self-limiting chest pain, intermittent palpitations and a single episode of pre-syncope. She has no significant medical history and takes no medications. She is currently pain free.

Vital signs
Temp 37 deg C
P 160 bpm
BP 168/100 mmHg
RR 20 /min
SaO2 95% on RA

i. List 4 relevant findings on the ECG (4 marks)

A 12 LEAD ECG IS SHOWN IN THE PROPS BOOKLET, PAGE 3

ii. List 4 initial treatment options with a brief rationale (4 marks)

The patient complains of feeling faint and looks pale and diaphoretic.

Vital signs
P 180 bpm
BP 100/70 mmHg
RR 30 bpm
SaO2 95% on RA

iii. Name the rhythm on the monitoring strip (1 mark) and list 3 possible treatment steps (3 marks)

A RHYTHM STRIP IS SHOWN IN THE PROPS BOOKLET, PAGE 4

iv. After treatment, the patient's haemodynamics improve and a repeat ECG is performed. List 3 relevant findings on the ECG (3 marks)

A 12 LEAD ECG IS SHOWN IN THE PROPS BOOKLET, PAGE 5

v. List 3 possible causes (3 marks)

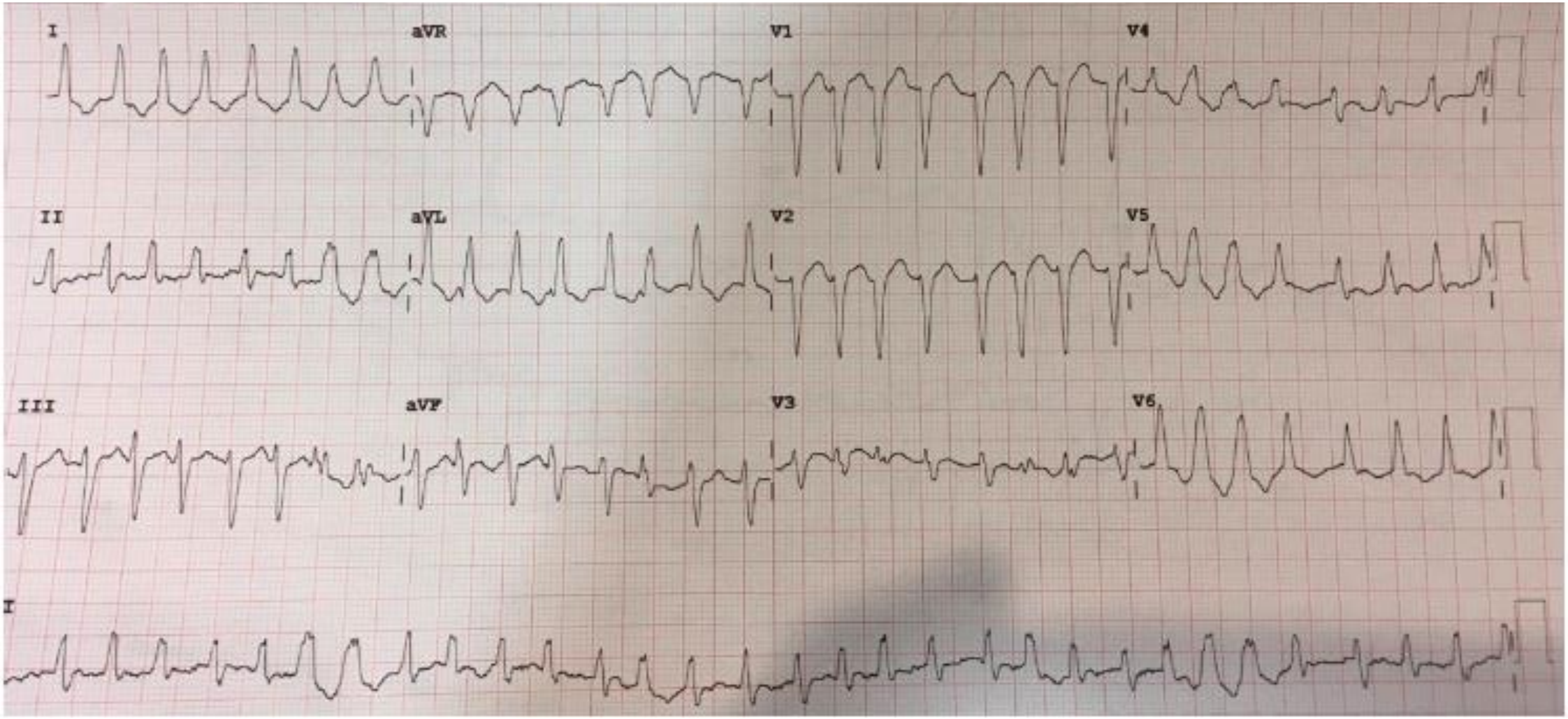
I
aVR
V1
V4
II
aVL
V2
V5
III
aVF
V3
V6
I

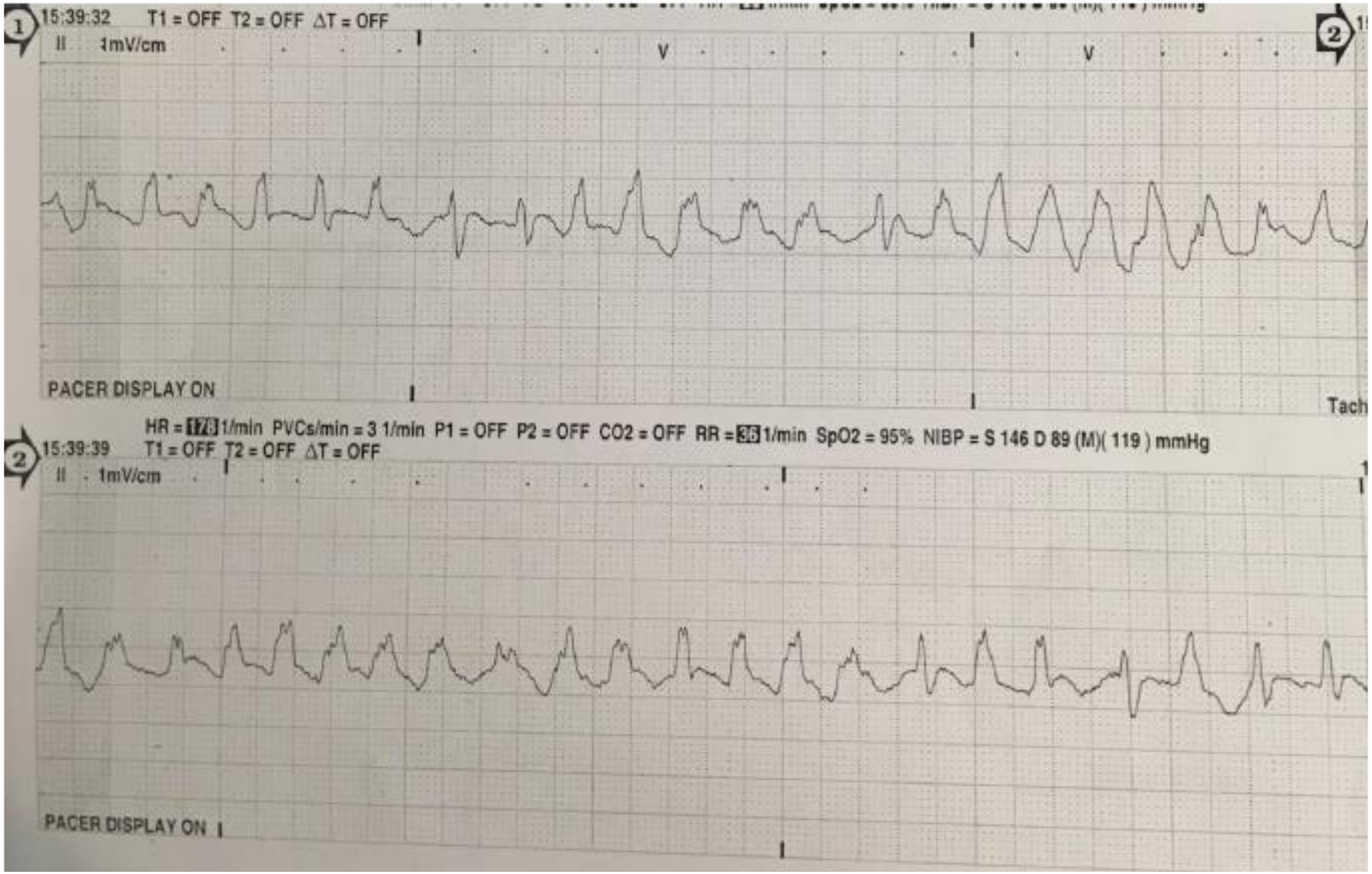
15:39:32 T1 = OFF T2 = OFF ΔT = OFF
II 1mV/cm
PACER DISPLAY ON
HR = 178 1/min PVCs/min = 3 1/min P1 = OFF P2 = OFF CO2 = OFF RR = 36 1/min SpO2 = 95% NIBP = S 146 D 89 (M)(119) mmHg
15:39:39 T1 = OFF T2 = OFF ΔT = OFF
II 1mV/cm
PACER DISPLAY ON

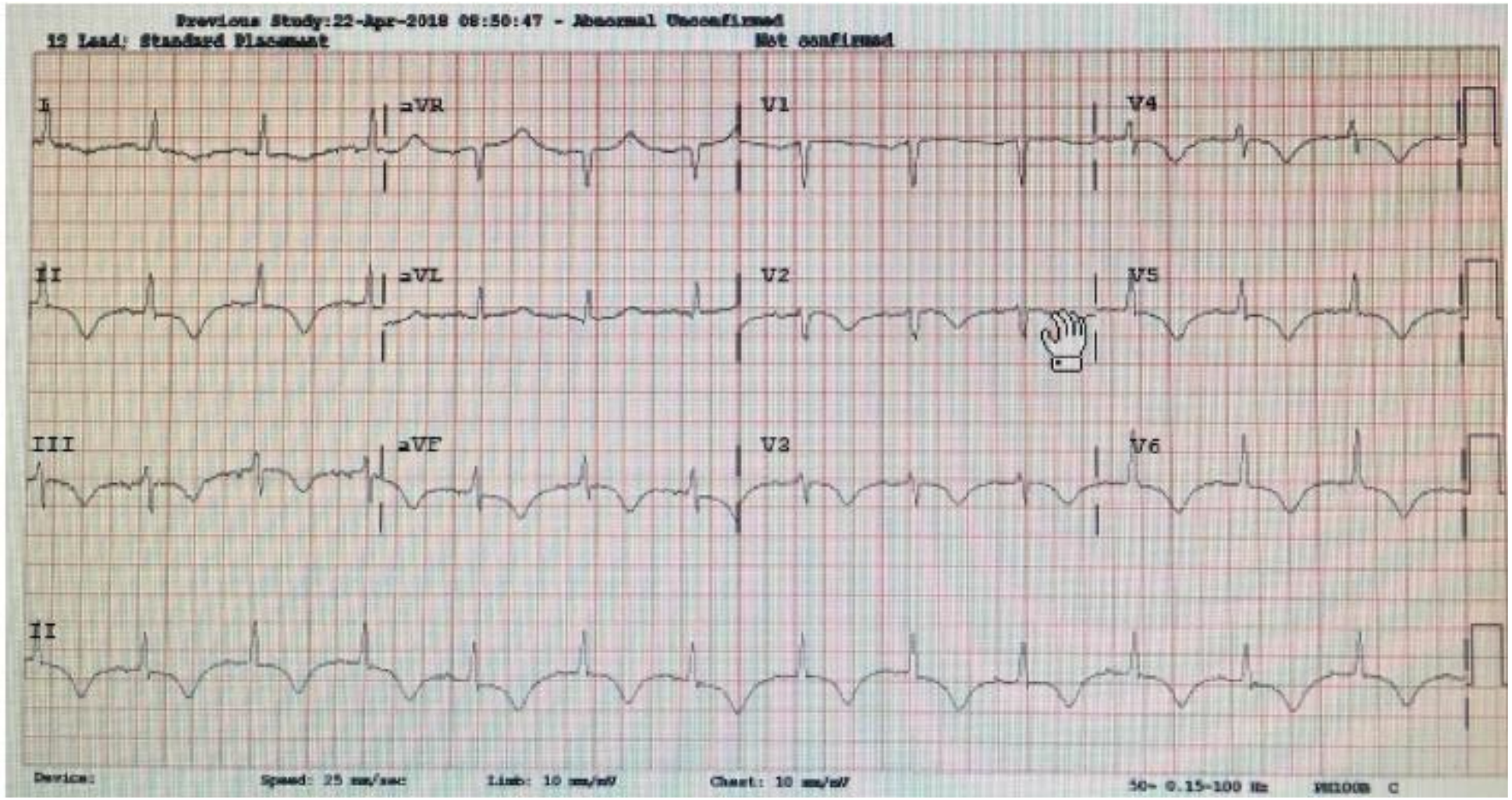
Previous Study:22-Apr-2018 08:50:47 - Abnormal Unconfirmed
12 Lead: Standard Placement
Not confirmed
I
aVR
V1
V4
II
aVL
V2
V5
III
aVF
V3
V6
II
Device:
Speed: 25 mm/sec
Limb: 10 mm/mV
Chest: 10 mm/mV
50~ 0.15-100 Hz

A 37 year old man presents with chest pain following cocaine use.

i. List and explain three ways in which cocaine use may cause chest pain (6 marks)

During the assessment the patient has a brief self-limited seizure.

Vital signs RR 12 bpm
P 130 bpm
BP 140/69 mmHg
SaO2 95% on RA
Temp 37 deg C

ii. An ECG is performed. Describe and interpret the ECG (2 marks)

A 12 LEAD ECG IS SHOWN IN THE PROPS BOOKLET, PAGE 6

iii. Describe two pharmacodynamics properties of cocaine that lead to tachydysrhythmias (2 marks)

iv. Outline your approach to the treatment of this tachydysrhythmia (3 marks)

v. Beta-selective adrenoreceptor blockers have traditionally been contraindicated in this setting. Why? (2 marks)

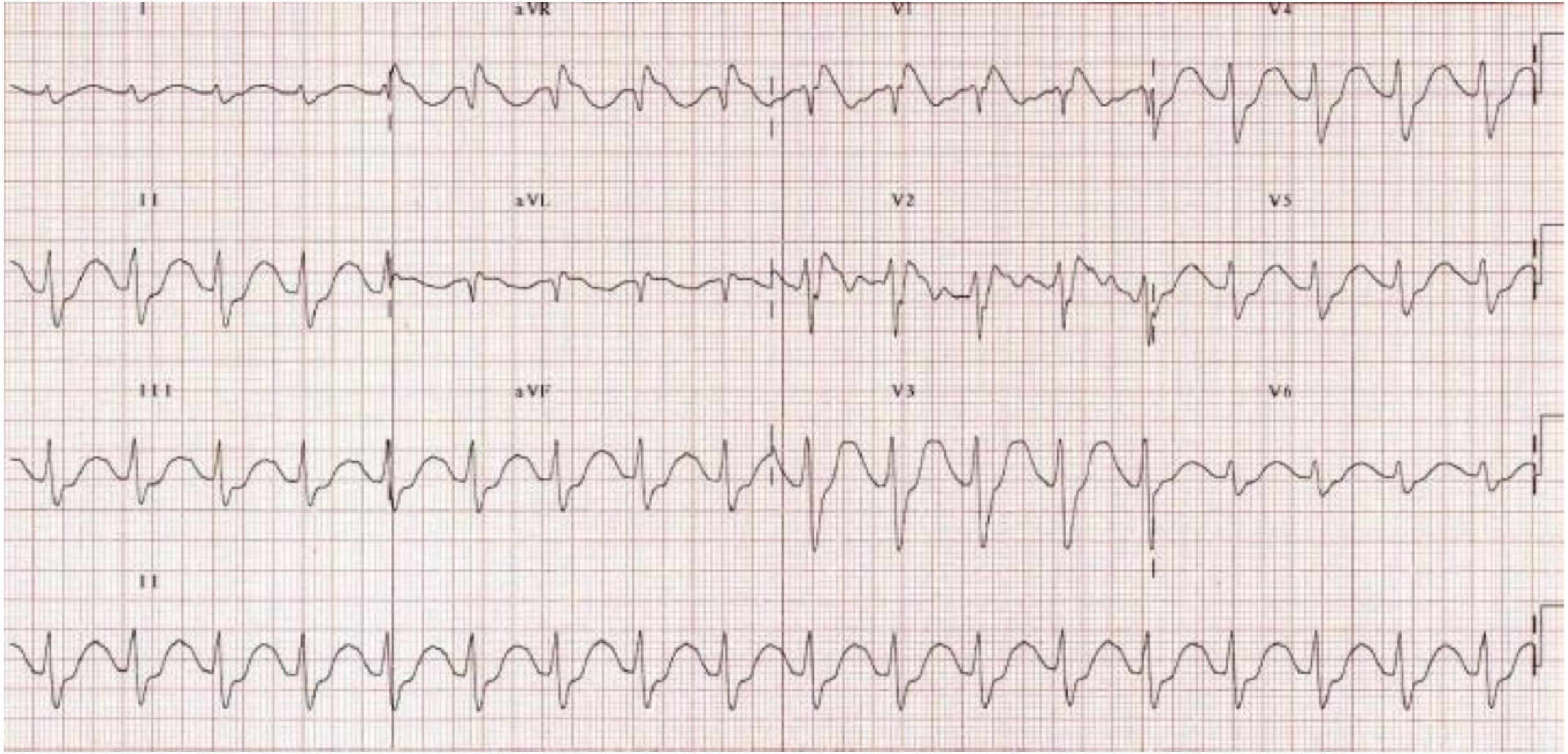
I
aVR
V1
V4
II
aVL
V2
V5
III
aVF
V3
V6
II

A 57 year old male presents with chest pain.

i. Complete the following table providing details of the "HEART Score" (5 marks)

Criterion	Description/Details	Score
History		2
		1
		0
ECG		2
		1
		0
Age		2
		1
		0
Risk factors		2
		1
		0
Troponin		2
		1
		0

ii. For each risk "band" obtained by calculating a HEART Score, list the predicted risk of a major adverse cardiac event (MACE) (3 marks)

HEART Score	Risk of MACE
0-3 Low risk	
4-6 Intermediate risk	
7-10 High risk	

iii. This patient is "low risk" on his HEART score but insistent on further testing. You are aware that exercise stress testing in low risk patients is controversial. Explain why this is so from a biostatistics viewpoint (2 marks)

iv. Provide a definition for *shared decision making* (2 marks) and outline barriers to the use of *shared decision making* in the ED (2 marks)

Your resident has just seen a 30 year old man with chest pain suspicious for pericarditis.

i. List 3 criteria which should be met to make a diagnosis of pericarditis (3 marks)

ii. The resident could not hear a pericardial rub. Detail how to auscultate for a pericardial rub and describe what sound might be expected (3 marks)

iii. List 4 ECG features that help to distinguish Benign Early Repolarisation (BER) from pericarditis (4 marks)

iv. Pericarditis is the working diagnosis for this patient and a decision is made to commence an NSAID and colchicine. Outline the progression of clinical features in colchicine overdose (3 marks)

A 55-year old man presents to the ED with sudden onset of severe chest and interscapular back pain with diaphoresis.

Vital signs are as follows:

HR 105 bpm
BP 190/95mmHg
SaO2 95% room air

A CTPA is performed:

1. What is the diagnosis? (0.5 mark).

Diagnosis: _____

2. List 4 signs that you might expect to see on physical examination (4 marks).

i. _____

ii. _____

iii. _____

iv. _____

3. List and justify 3 investigations for this patient (1.5 marks).

	Investigation	Justification
1.		
2.		
3.		

4. What is the definitive treatment for this condition? (1 mark)

_____

_____

5. List 3 drugs you would administer in ED, along with a therapeutic indication for each. (3 marks)

	Drug	Indication
1.		
2.		
3.		

A 62 year old male presents to your small rural Emergency Department with 30 minutes of central heavy chest pain with some radiation into the throat and some belching.

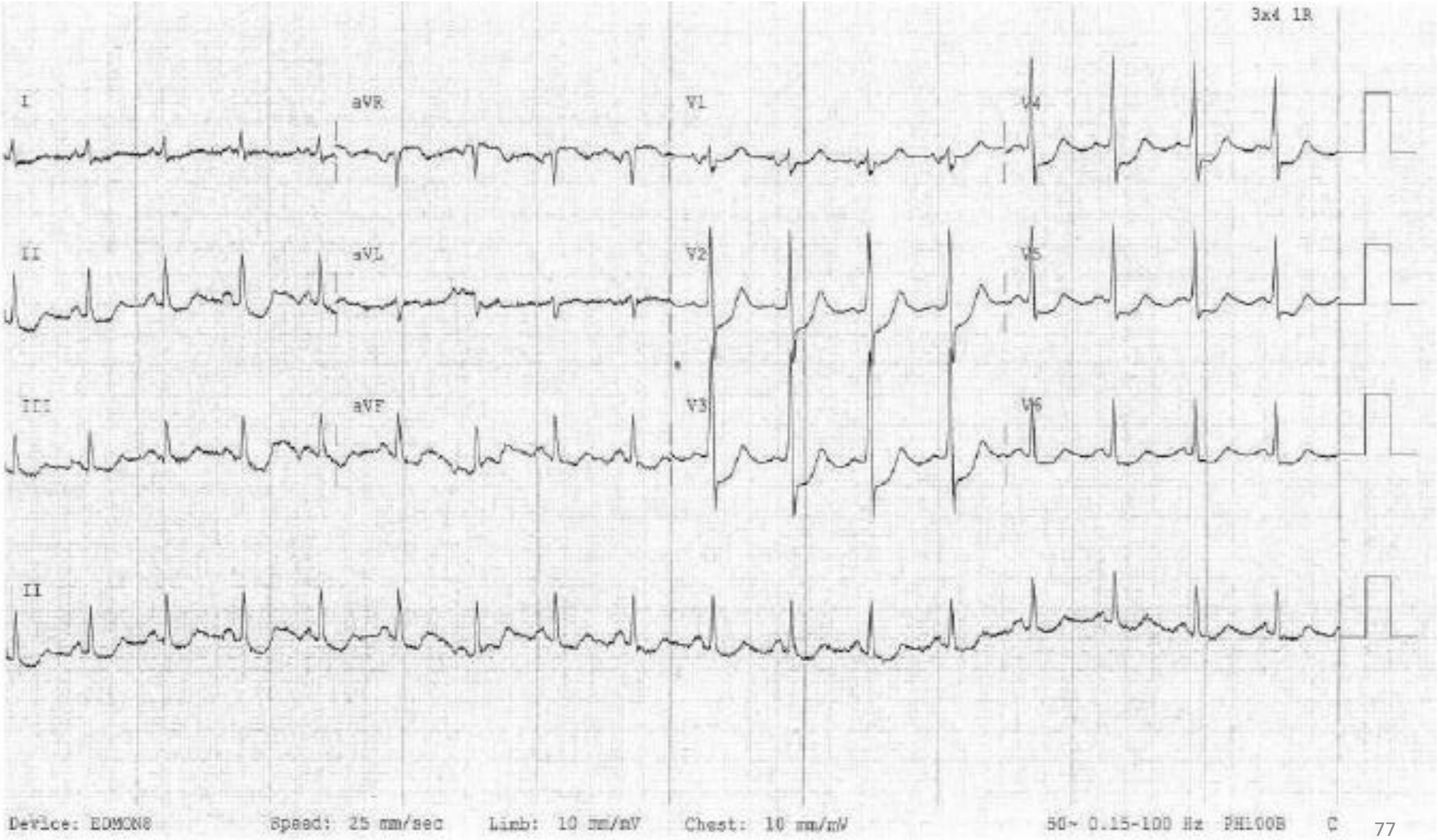

1. Identify the abnormalities on the ECG (4 marks).

_____

_____

_____

_____

2. Where are the most likely areas of concern in the coronary arteries? (2 marks).

_____

_____

_____

_____

3. What are the 4 priorities in managing this case? (4 marks).

   i. _____

   ii. _____

   iii. _____

   iv. _____

A 30 year old man presents to the emergency department with fever of 38.5 and chest pain and SOB. He reports that he is an IVDU. On examination, he has bibasal crepitations and a murmur which was not present on previous presentations.

1. What is the most likely diagnosis? (1 mark).

_____

2. List **4** components of Dukes Criteria (4 marks).

   i. _____

   ii. _____

   iii. _____

   iv. _____

3. Name **2** of the most common organisms which cause this pathology in the IVDU population (2 marks).

   i. _____

   ii. _____

4. What antibiotics would you use to treat it? (3 marks).

_____

_____

_____

Your registrar brings you the ECG of a 46 year old man who has presented with palpitations. He is in a Resus bay, being monitored. His condition is stable with BP 120/80, Sats 99% RA, RR18, and GCS 15.

1. What are **4** ECG features of VT that you look for in making a diagnosis? (2 marks).

   i. _____

   ii. _____

   iii. _____

   iv. _____

The ECG shows a wide complex tachyarrhythmia.

2. What else could this be (apart from VT)? (2 marks).

_____

_____

3. What are **3** treatment options for this man <u>with pros and cons of each</u>? (6 marks).

   i. _____

   _____

   ii. _____

   _____

   iii. _____

   _____

A 64 year old woman has presented with 3 hours of chest pain.

She has a history of type 2 diabetes mellitus and hypertension.

Her ECG is reproduced in the **PROPS BOOKLET**.

1. **List 4 key findings on her ECG.** **(4 marks)**

_____

_____

_____

_____

2. **Give your interpretation of this ECG and its clinical relevance.** **(2 marks)**

_____

_____

Upon your assessment the patient looks pale and sweaty. She has full field crackles on lung auscultation.

Her vital signs are:

GCS	13	E3 V4 M6
Pulse	70	/min
BP	75/40	mmHg
O2 saturation	88%	15L O2 via non-rebreather mask

You have decided that the patient needs intubation as part of her ongoing management.

3. **List 5 modifications to a standard RSI that you would employ in this patient.** **(5 marks)**

1) _____

_____

2) _____

_____

3) _____

_____

4) _____

_____

5) _____

_____

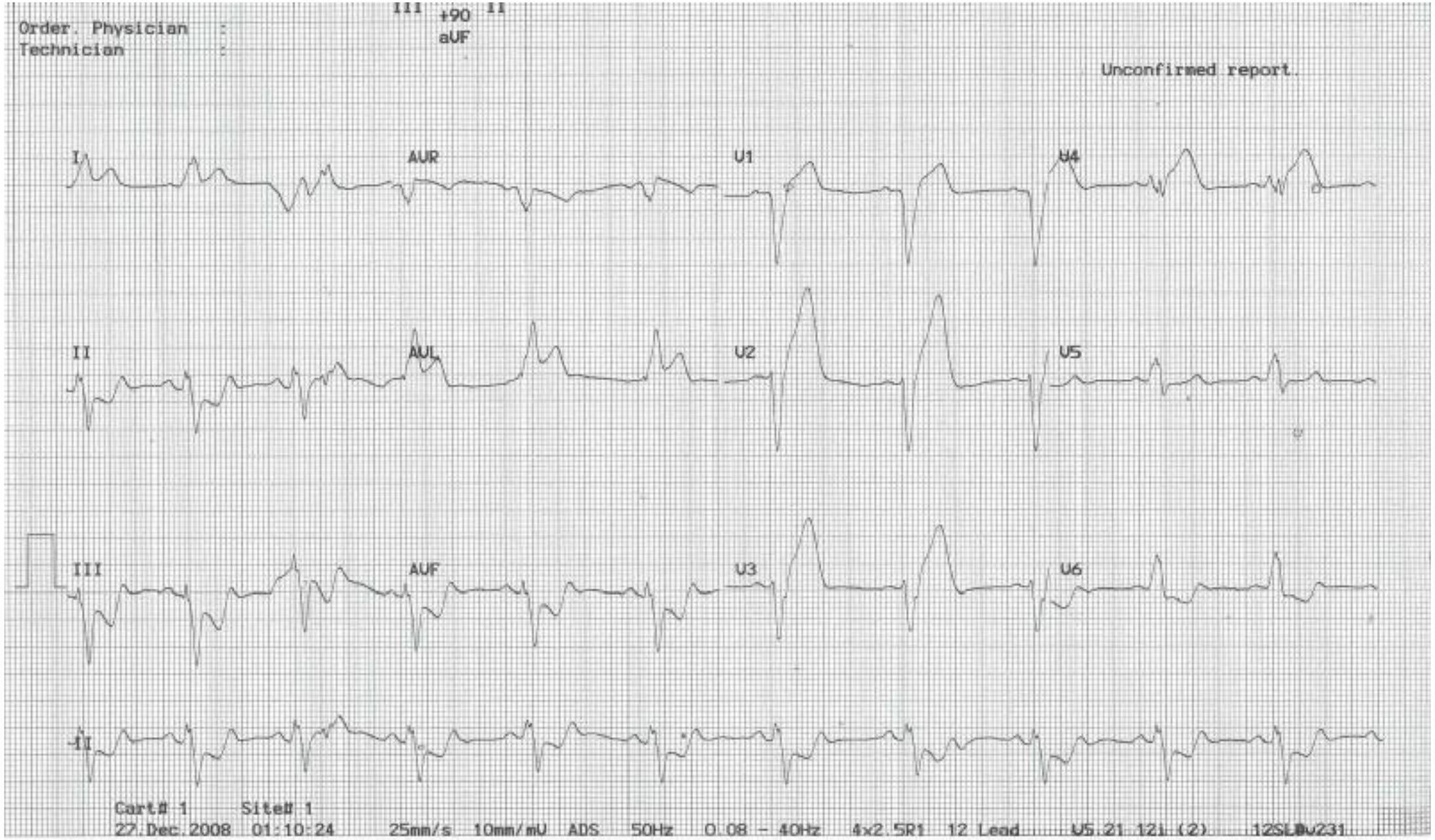
Order. Physician :
Technician :
III +90 II
aUF
Unconfirmed report.
I
AUR
U1
U4
II
AUL
U2
U5
III
AUF
U3
U6
II
Cart# 1 Site# 1
27.Dec.2008 01:10:24 25mm/s 10mm/mV ADS 50Hz 0.08 - 40Hz 4x2.5R1 12 Lead U5.21.121.(2) 12SL@v231

A 47 year old male presents with epigastric pain for the past 45 minutes.

i. Describe and interpret the ECG (4 marks)

A 12 LEAD ECG IS SHOWN IN THE PROPS BOOKLET, PAGE 5

ii. Describe and justify your immediate pharmacological treatment (4 marks)

iii. His pain settles with aliquots of fentanyl but the ECG changes persist. You are 90 minutes away from a PCI centre. Describe and justify your reperfusion plan (3 marks)

iv. List 5 absolute contraindications to fibrinolysis (5 marks)

v. What constitutes failure of fibrinolysis, suggesting need for a rescue PCI (3 marks)

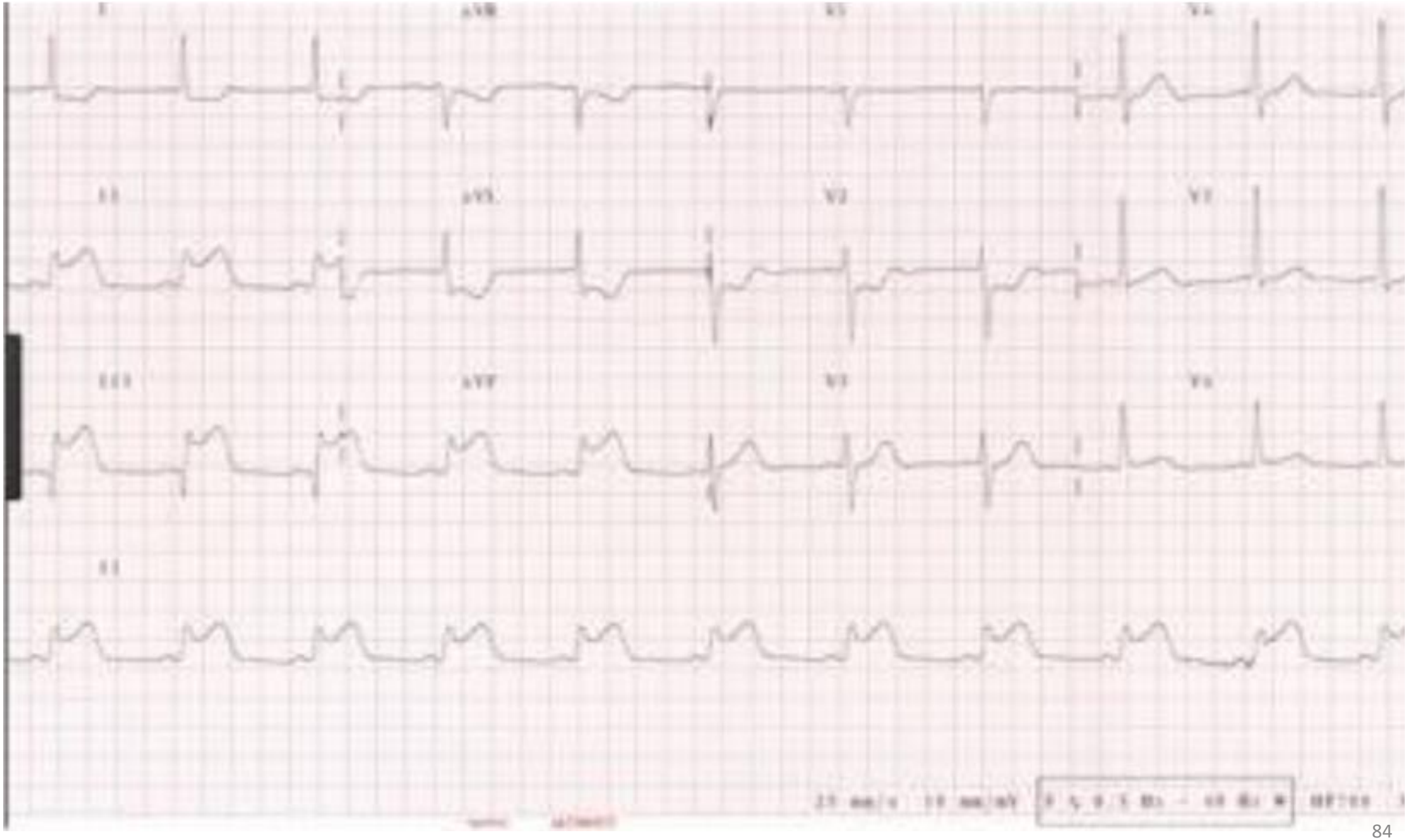

An 89 year old woman is brought to your tertiary ED with sudden severe chest pain and collapse with transient loss of consciousness.

Vital signs BP 90/- mmHg
HR 50 bpm
GCS 12

i. List 4 potentially life threatening diagnoses (4 marks)

ii. What are the three most useful diagnostic tests in this setting (3 marks)

iii. What is the major abnormality on this bedside sub-sternal ultrasound image and what is the likely clinical diagnosis (2 marks)

AN ULTRASOUND IS SHOWN IN THE PROPS BOOKLET, PAGE 12

iv. What two treatment approaches are available (2 marks)

v. The family arrives with an Advance Care Directive stating the patient did not want any lifesaving surgery. Prescribe the PRN meds you would chart for the ward (3 marks)

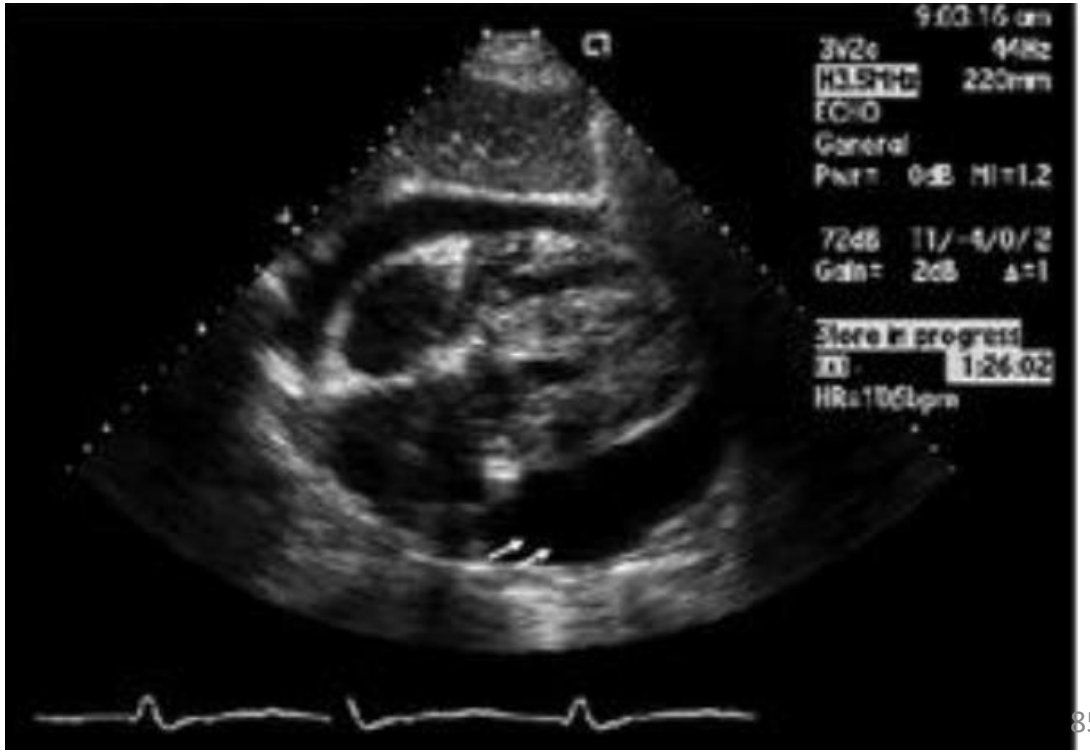

A 65 year old man has presented to your regional ED with acute onset SOB and chest pain. His pain is severe and radiates to his back.

Vital signs:	HR	125 bpm
	BP	98/52 mmHg
	RR	22 bpm
	SaO2 RA	96%
	Temp	37.2 deg C

i. List 4 important features on this ECG (4 marks)

A 12 LEAD ECG IS SHOWN IN THE PROPS BOOKLET, PAGE 3

ii. List 4 features on a CXR that would raise your suspicion of acute aortic dissection (4 marks)

iii. What features on bedside US would help differentiate acute MI from aortic dissection as the cause of shock (4 marks)

iv. CT imaging is unavailable. Given the patient's history and clinical examination you treat him for an acute aortic dissection. List 6 management steps (6 marks)

v. List a classification of aortic dissections (2 marks)

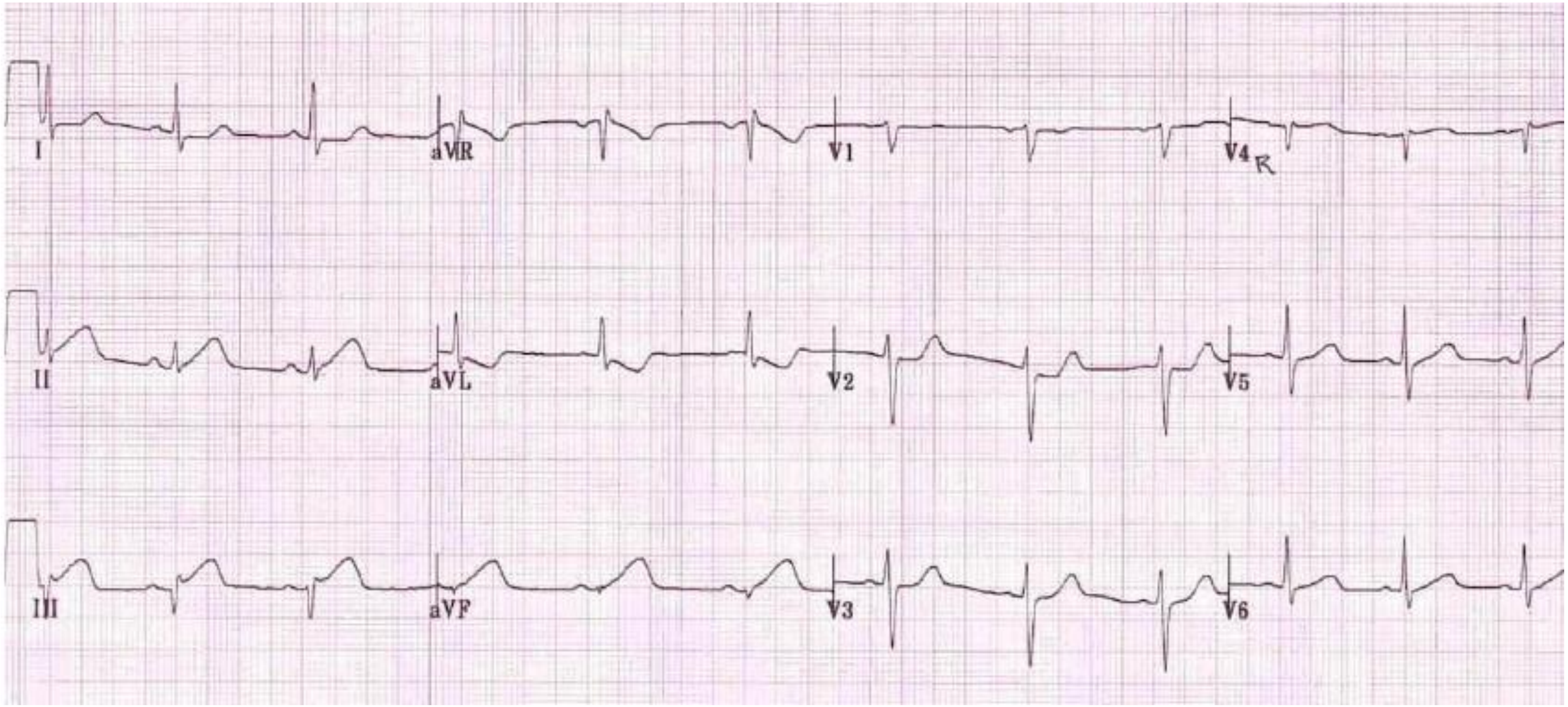
I
aVR
V1
V4R
II
aVL
V2
V5
III
aVF
V3
V6

A 72 year old male presents via ambulance short of breath. He is sweaty and looks unwell but is conscious. He has a history of IHD and has an AICD in situ.

Vital signs	P 150 bpm
	BP 75/- mmHg
	RR 30 bpm
	SaO2 96% 15LNRB

i. What rhythm is shown (1 mark)

A 12 LEAD ECG IS SHOWN IN THE PROPS BOOKLET, PAGE 8

You decide to perform DC cardioversion to treat the rhythm noted above. A VBG done after a cannula is placed shows the following.

pH	7.35	(7.35-7.45)
pCO2	57 mmHg	(32-45)
Lactate	3.3 mmol/L	(0.5-1.6)
K	6.1 mmol/L	(3.5-5.2)
Cr	160 mcmol/L	(60-110)

ii. What other treatment is required while cardioversion is being arranged (2 marks)

iii. Outline 2 pharmacologic agents you could use for sedation in this patient with initial doses and indicating an advantages and disadvantage for each (8 marks)

Drug	Dose	Advantage	Disadvantage

iv. Describe what settings you would set on the defibrillator and the positioning of the pads on the patient (2 marks)

v. After cardioversion with sedation his rhythm is as follows. Describe the rhythm (1 mark)

A RHYTHM STRIP IS SHOWN IN THE PROPS BOOKLET, PAGE 8

vi. Despite the ECG change the patient remains hypotensive, P 100bpm, SBP 80mmHg. Give 2 differential diagnoses for this (2 marks)

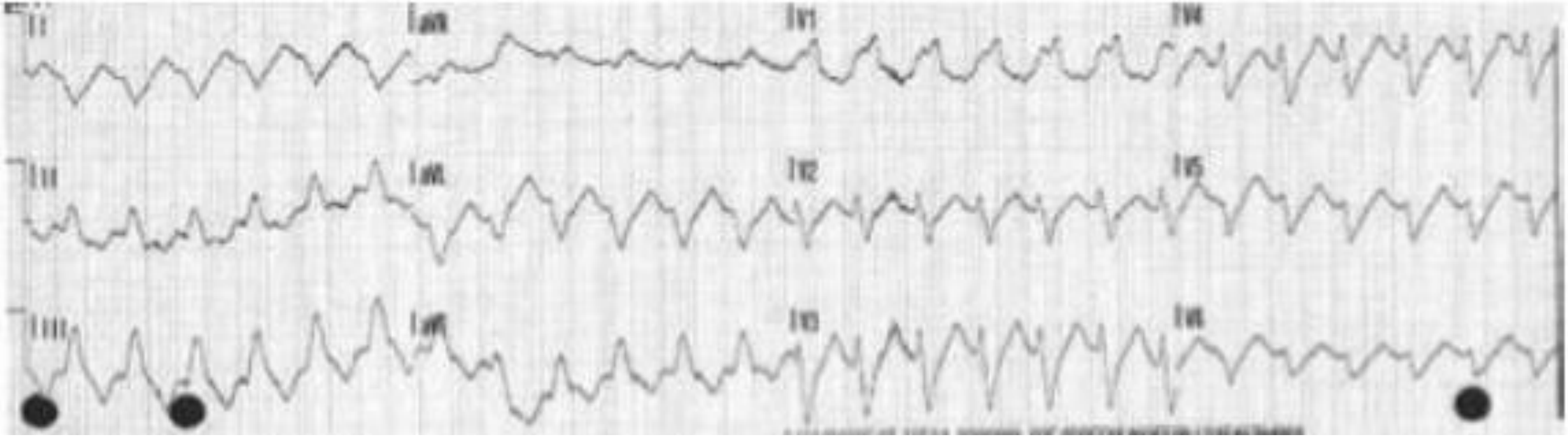

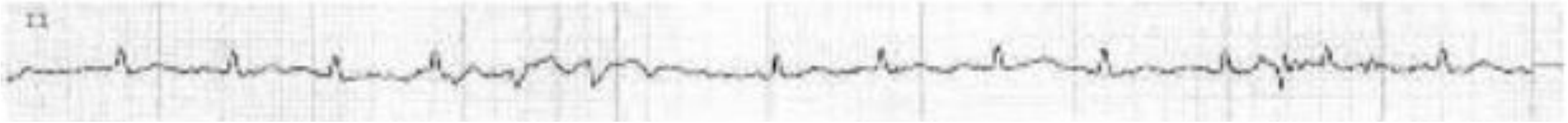

A 41 year old man presents with a brief syncopal episode. He has no significant past medical history, medications or allergies. On examination he is alert and cardio-respiratory exam is normal.

Vital signs	HR	96 bpm
	BP	135/80 mmHg
	RR	12 bpm
	SaO2 RA	96%
	Temp	36.5 deg C
	BSL	5 mmol/L

i. Describe the most significant finding on this ECG and state the most concerning diagnosis given the clinical setting (2 marks)

A 12 LEAD ECG IS SHOWN IN THE PROPS BOOKLET, PAGE 9

ii. List 4 differential diagnoses for this ECG pattern (4 marks)

iii. List 4 relevant questions you would ask the patient (4 marks)

iv. Outline the important components of his disposition, follow-up and ongoing management (4 marks)

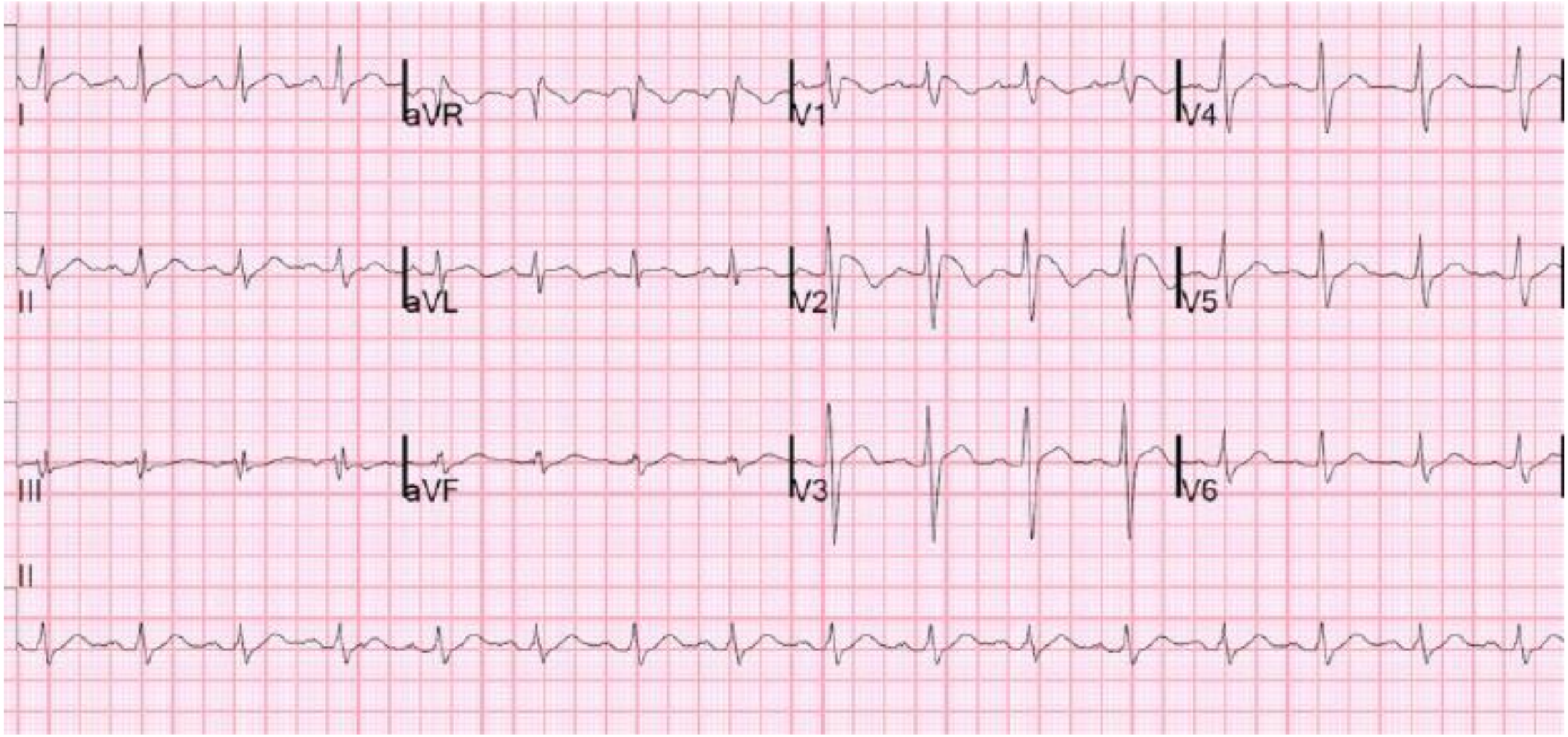
I
aVR
V1
V4
II
aVL
V2
V5
III
aVF
V3
V6
II

A 55yo male farm hand attends with palpitations for 8 hours and is found to be in AF. He has no history of rheumatic fever, IHD, hypertension, valvular heart disease, previous cerebral ischaemia, peripheral vascular disease or diabetes. He is normotensive and has no ECG evidence of ischaemia. This is his first episode. Apart from the AF his echo is normal.

(a) Calculate his $CHADS_2$ score

(a) What is the purpose of this score

(a) What is the purpose of the HASBLED score

In the table below List 4 pharmacologic management options for this patient and list two clinically important pros (excluding hypersensitivity reactions) for each

Medication	Pros	Cons
1.	1(i).	1(i)
	1(ii)	1(ii)
2.	2(i)	2(i)
	2(i)	2(ii)
3.	3(i)	3(i)
	3(ii)	3(ii)
4.	4(i)	4(i)
	4(ii)	4(ii)

A 55yo male is BIBA with severe CP of 45 minutes duration. He has had oxygen, 600mcg of GTN, 300mg of oral aspirin followed by 250mls of NS for hypotension. ECG attached (assume standard calibration and paper speed)

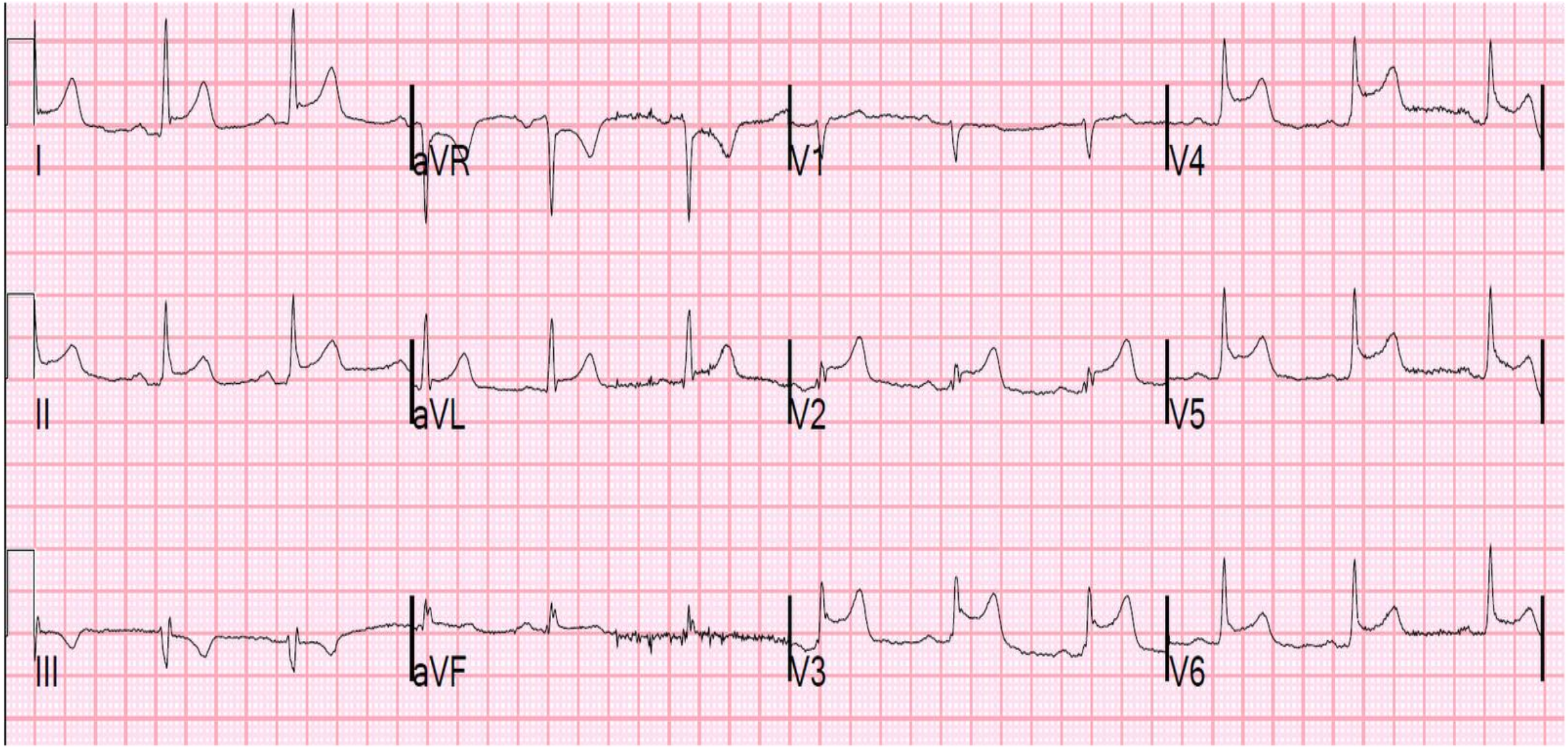

(a) What is the diagnosis from this ECG? (15%)

(a) What are the most likely causes for acute hypotension in this setting? (30%)

(b) What are the principal interventions for cardiogenic shock in AMI? (20%)

(a) List 8 absolute contraindications to giving fibrinolytic therapy. (35%)

A 74yo, normally active and independent female presents with light headedness. PR 30bpm, BP 70/40. She is on no medications. She denies chest pain at any stage.

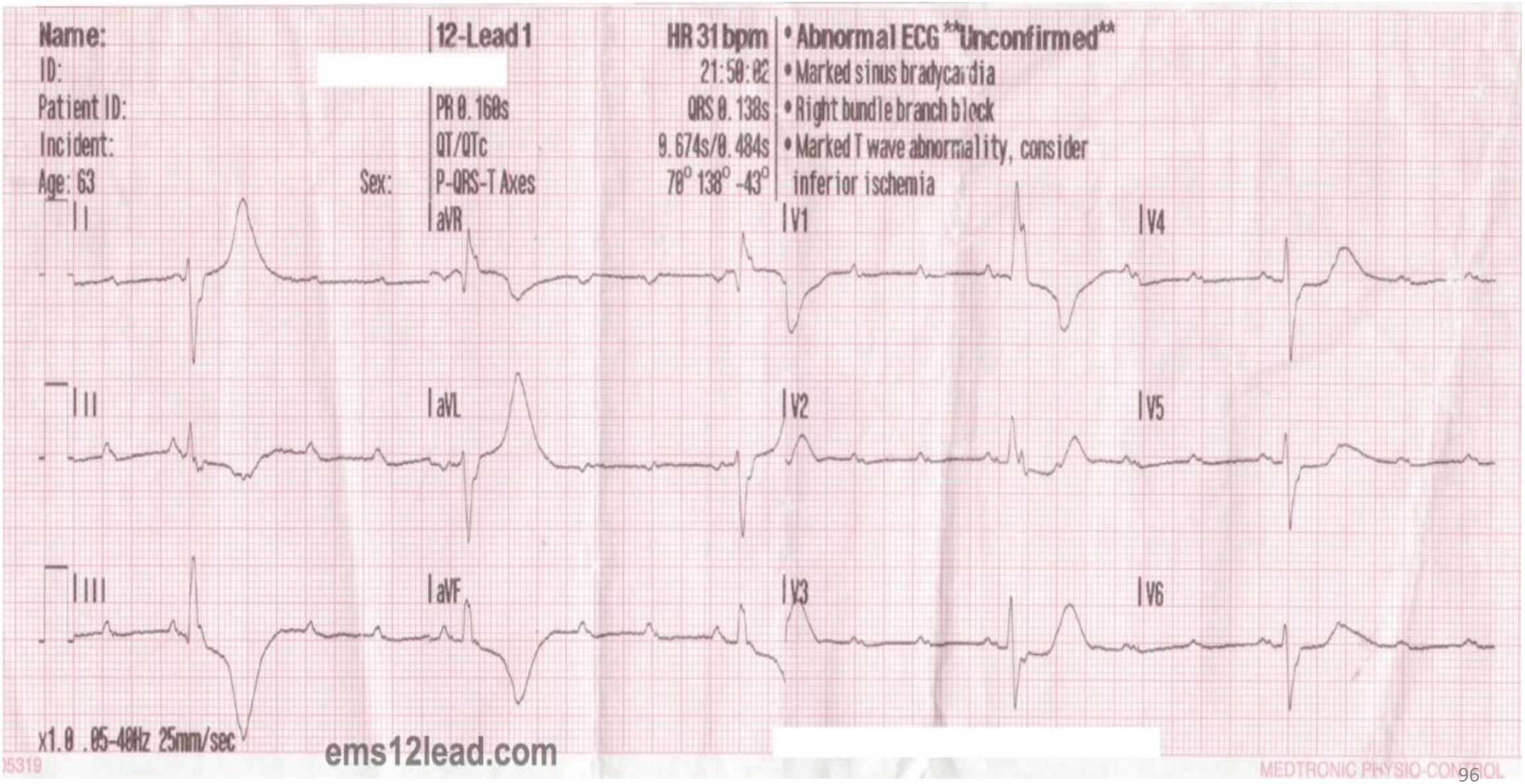

(a) What is the diagnosis from this ECG? (20%)

(b) What are your options for managing this condition acutely? (40%)

(c) Describe the steps in external pacing (40%)

A 14 year old girl presents to your Emergency Department after having a conscious collapse at school. She appears underweight and is clinically dehydrated. An ECG is performed and is shown below.

a. List 3 abnormalities seen on the ECG above: (3 marks)

b. What is the most likely cause of this patient's presentation, taking into account the ECG findings? (1 mark)

c. Name the 4 most useful investigations in confirming the most likely diagnosis and its underlying cause. (4 marks)

d. List in point form 6 major points of management of this patient if your most likely diagnosis is confirmed. (6 marks)

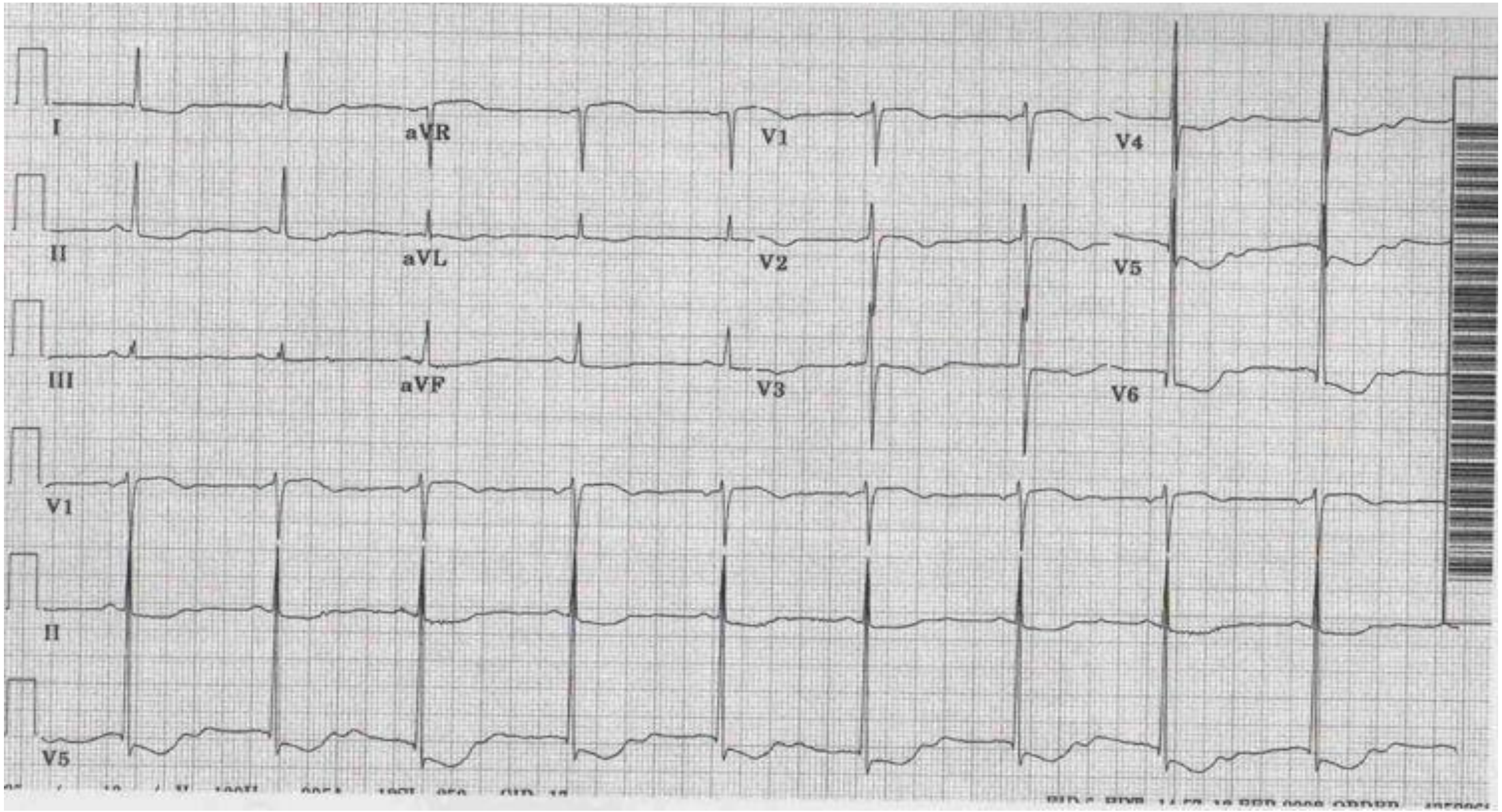
I
aVR
V1
V4
II
aVL
V2
V5
III
aVF
V3
V6
V1
II
V5

The pictures below were taken of a 26 year old woman who presented to your emergency department with a febrile illness. She has a history of current intravenous recreational drug use.

a) List 6 further examination findings that would support the most likely diagnosis: (6 marks)

b) List 4 investigations you would order for this patient to support/confirm this diagnosis with justification for each. (8 marks)

Investigation:	Justification:

The photograph below is a simulation of a procedure which may be performed in the emergency department.

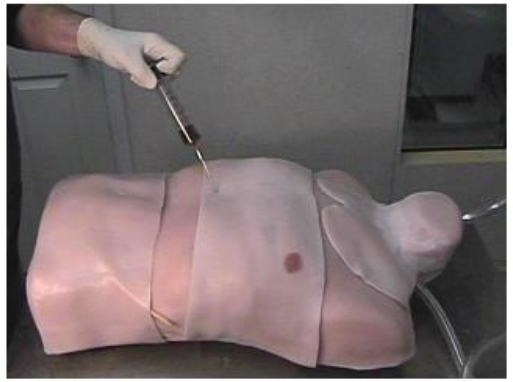

a. Name the indication for performance of the procedure demonstrated above in the emergency department? (2 marks)

b. List 4 possible complications which may occur as a result of performing this procedure: (4 marks)

c. List 8 possible causes for clinically significant, nontraumatic pericardial effusion (8 marks):

A 36 year old man presents to your emergency department complaining of 3 hours of central chest discomfort. The pain is heavy, worse on deep inspiration and radiates to his back. He is a smoker but denies use of other recreational drugs. His father had Ischaemic heart disease and a myocardial infarction aged 62 years. There is no other significant past medical or family history. Examination reveals a HR 105bpm, BP 135/70, saturations 99% on room air and a temperature of 37.5 C. Cardiorespiratory examination is unremarkable. An ECG is performed and is shown below.

(a) List 4 abnormal findings on the above ECG (4 marks):

(b) List the 4 most probable aetiologies for this patient's presentation and identify the most useful first line investigation for diagnosing each. (8 marks)

Aetiology/diagnosis:	Investigation:

c) List two findings on examination that would clinically support one of your listed differential diagnoses: (2 marks)

Test ind: EKG CHANGES

Referred by: PATE

Unconfirmed

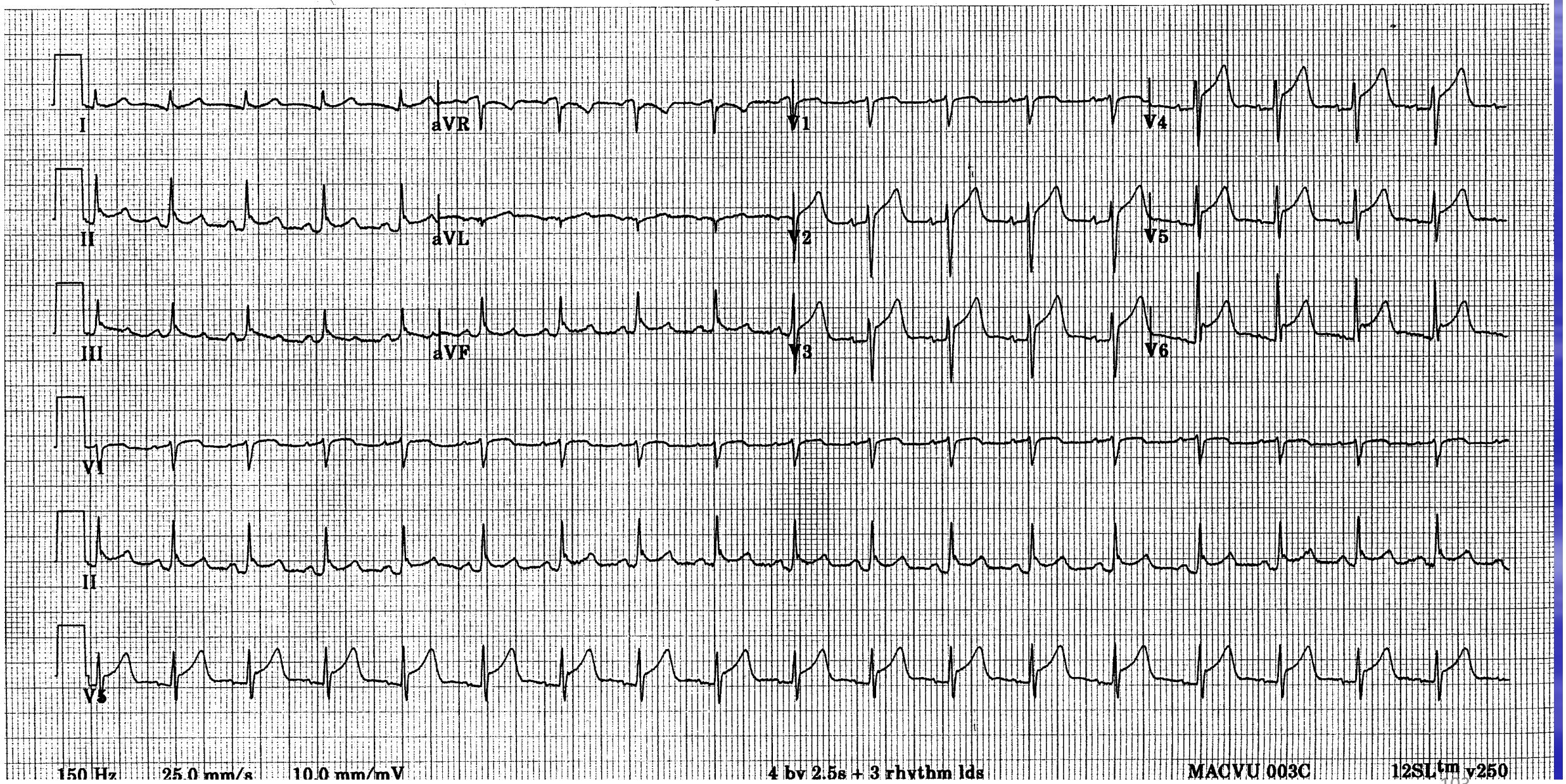

A 70 year old man presents to your resuscitation room. He is acutely SOB and has a previous history of ischaemic cardiomyopathy. A CXR is performed and is shown below.

a) Name 2 features of the above CXR that support the most probable diagnosis: (2 marks)

b) List 4 contraindications to CPAP being used in this patient? (4 marks)

c) List 4 possible contraindications for intubation and ventilation in this patient? (4 marks)

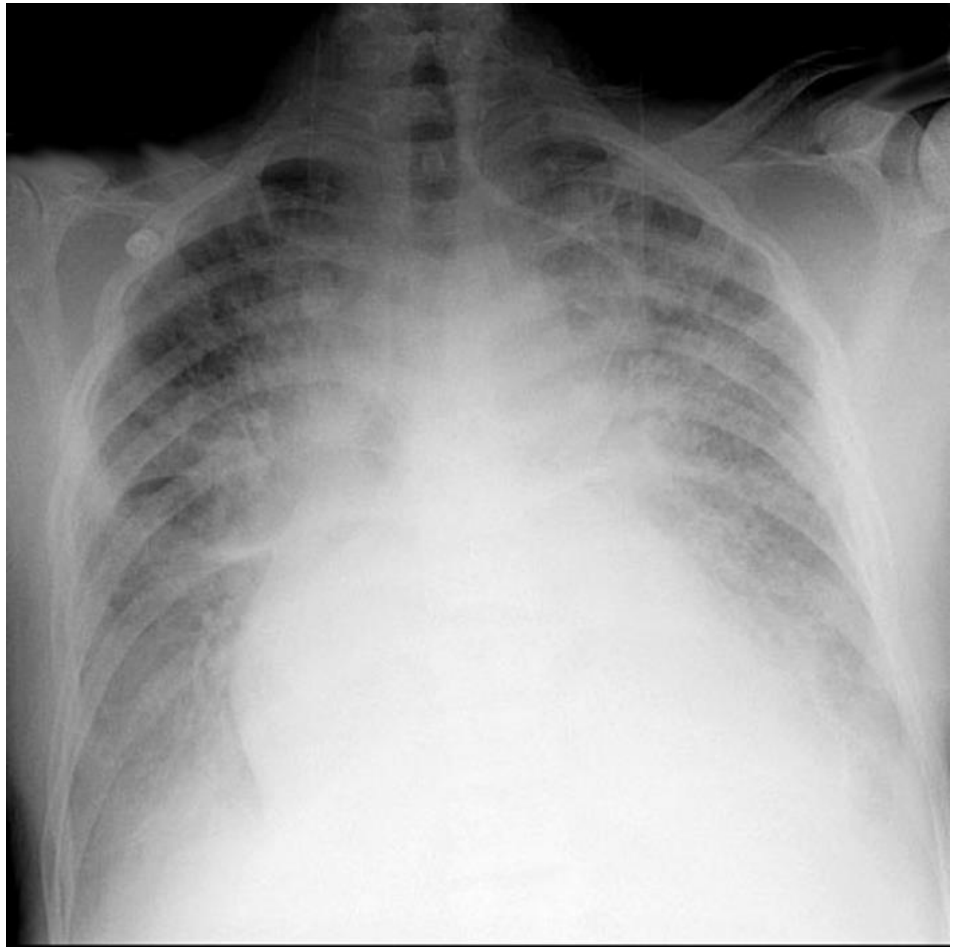

d) If intubation and ventilation were to occur, list your drug choice, including doses, together with justification for your choices. (4 marks)

Drug:	Justification:

A 37 year old man is brought to you resuscitation room after falling 6 metres from a tree. He complains of thoracic and abdominal pain. He has a blood pressure of 80 systolic, GCS of 15 and saturations on 8 L/min via mask of 98%. An ECG is performed as demonstrated above.

a) Identify the ECG rhythm: (1 mark)

b) List 4 possible aetiologies of the above ECG abnormality in this patient: (4 marks)

c) Name 3 options for management of this rhythm in this patient: (3 marks)

d) Choose 1 option from your list above and give 4 reasons with regards to risk-benefit analysis as to why you have chosen it in preference. (6 marks)

I
aVR
V1
V4
II
aVL
V2
V5
III
aVF
V3
V6
II
50 Hz
25.0 mm/s
10.0 mm/mV
4 by 2.5s + 1 rhythm ld
MAC5K 005A
12SL™v231

You work in a rural emergency department with only basic specialties represented. An 80 year old man is delivered to your emergency department with an acute anterior ST elevation myocardial infarction. He has had severe central chest pain for 2 hours which is ongoing. He is anxious, pale and diaphoretic, with widespread crepitations heard throughout his lung fields. Obs reveal GCS 15, HR 100, BP 190/100, RR 24 and oxygen saturations 36.8 C Local retrieval services are unable to support transfer of this patient to a higher level facility for at least 4 hours.

a) List 2 proposed clinical benefits of thrombolysis in this patient (2 marks)

b) List the absolute contraindications to fibrinolytic treatment in patients with acute myocardial infarction. (6 marks)

c) Name 2 significant mortality risks associated with thrombolytic therapy in patients with acute myocardial infarction (2 marks)